



## Knee arthrodesis using a unilateral external fixator for the treatment of infectious sequelae

### *Enfeksiyon sekeli tedavisinde unilateral eksternal fiksator ile diz artrodezi*

Levent ERALP, Mehmet KOCAOGLU, Ibrahim TUNCAY,<sup>1</sup> F. Erkal BILEN,<sup>2</sup> Shady Elbeshry SAMIR

*Istanbul Universitii Medical Faculty Department of Orthopaedic and Traumatology;*

*<sup>1</sup>Selçuk Üniversitesi Meram Tıp Fakültesi Ortopedi ve Travmatoloji Anabilim Dalı; <sup>2</sup>Serbest Hekim*

**Amaç:** Diz bölgesinin septik sekellerinin tedavisinde monolateral eksternal fiksator kullanılarak yapılan artrodez tekniğinin sonuçları değerlendirildi.

**Çalışma planı:** Monolateral eksternal fiksator kullanılarak diz artrodezi uygulanan 11 hasta (4 erkek, 11 kadın; ort. yaş 60; dağılım 29-75) geriye dönük olarak değerlendirildi. Altı hastada enfekte total diz protezi, dört hastada septik artrit sekeli, bir hastada enfekte distal femur modüler tümör protezi vardı. Aktif enfeksiyon bulunan sekiz hastanın yedisinde artrodez, debridman, antibiyotikli çimento uygulaması (n=6) ve parenteral antibiyoterapi ile enfeksiyon klinik ve laboratuvar bulguları tamamen kaybolduktan sonra uygulandı. Femur ve tibiada kanayan geniş bir kemik yüzeyi oluşturmak için total diz protezi uygulama setindeki rezeksiyon kızaqları kullanıldı. Biplanar veya uniplanar monolateral eksternal fiksasyon ortalama sekiz ay (dağılım 5-12 ay) uygulandı. Hastalar ortalama 28 ay (dağılım 7-69 ay) izlendi. Komplikasyonların değerlendirilmesi için Paley sınıflaması kullanıldı.

**Sonuçlar:** Tüm hastalarda eksternal fiksasyon sonunda füzyon elde edildi. Enfeksiyon nüksü görülmedi. Hiçbir hastada artrodez tekniğinden kaynaklanan istenmeyen kısalık görülmedi. Geniş tümör rezeksiyonu nedeniyle belirgin kısalık oluşan ve artrodezdten sonra uzatma uygulanan bir hasta dışında, tüm hastalar desteksiz yürüyebildi. Enfekte total diz protezi olan bir hastada kısalık 3 cm bulunurken, geri kalan hastalarda 1-2 cm arasında (ort. 1.4 cm) değişiyordu. Beş hastada görülen çivi dibi enfeksiyonu oral antibiyotik ve yara bakımı ile başarıyla tedavi edildi.

**Çıkarımlar:** Monolateral fiksator ile uygulanan diz artrodezinin füzyon oranı yüksek, komplikasyonları daha azdır; bu yöntem, sirküler eksternal fiksatorlere göre daha konforlu bir tedavi seçeneği oluşturmaktadır.

**Anahtar sözcükler:** Artrodez/yöntem; eksternal fiksator; diz eklemi/cerrahi; protezle ilişkili enfeksiyon/cerrahi.

**Objectives:** We evaluated the results of arthrodesis using a monolateral external fixator for the treatment of septic sequelae of the knee joint.

**Methods:** Eleven patients (4 males, 7 females; mean age 60 years; range 29 to 75 years) underwent arthrodesis using a monolateral external fixator. Indications for arthrodesis were infected total knee prosthesis (n=6), septic arthritis sequelae (n=4), and infected distal femoral tumor prosthesis (n=1). Eight patients had active infection; of these, seven patients initially underwent complete clinical and laboratory eradication of infection with debridement, application of antibiotic-impregnated cement spacer (n=6), and parenteral antibiotics. Resection guides of total knee arthroplasty were used to create wide bleeding femoral and tibial bone surfaces. Biplanar or uniplanar monolateral external fixation was applied for a mean of eight months (range 5 to 12 months). The mean follow-up was 28 months (range 7 to 69 months). Complications were evaluated according to the Paley's classification.

**Results:** Fusion was achieved in all the patients. There were no recurrent infections. No remarkable shortening developed following the procedure. All the patients could walk without walking aids, except for one patient who further required lengthening for marked shortening due to previous wide tumor resection. Shortening was 3 cm in one patient with infected total knee prosthesis, while it ranged from 1 cm to 2 cm (mean 1.4 cm) in the remaining patients. Pin tract infections were seen in five patients, all of which were successfully treated with oral antibiotics and local wound care.

**Conclusion:** Knee arthrodesis using a monolateral external fixator is associated with a high fusion rate and a low complication rate, and provides a more comfortable treatment option compared to a circular external fixator.

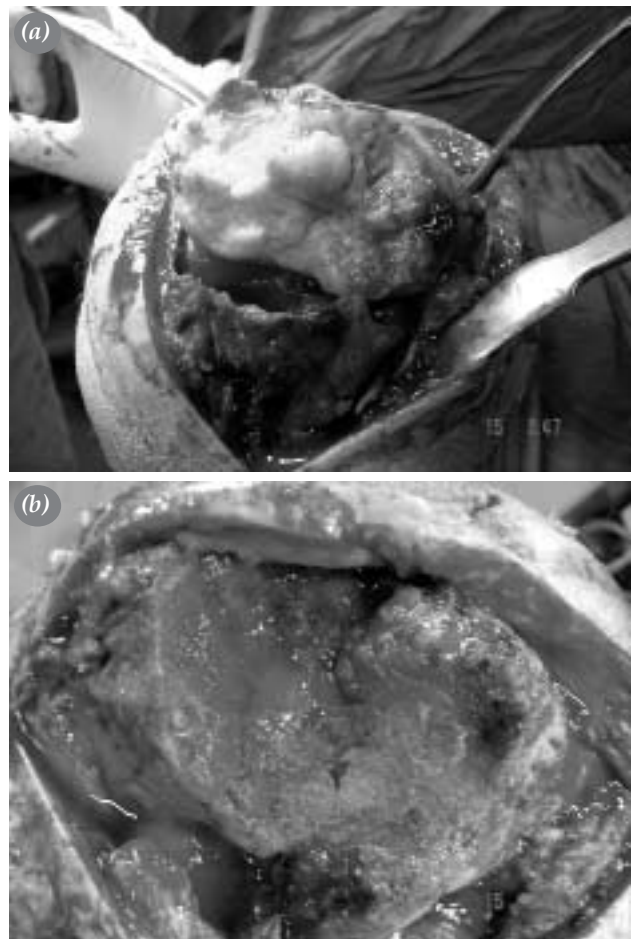
**Key words:** Arthrodesis/methods; external fixators; knee joint/surgery; prosthesis-related infections/surgery.

Arthrodesis of the knee is being performed since the early 1900's for the treatment of pain and instability due to advanced osteoarthritis, posttraumatic arthritis, infectious arthritis, Charcot arthropathy, poliomyelitis, and reconstruction following tumor resection.<sup>[1]</sup> The success of modern knee arthroplasty has decreased the number of patients who would have been candidates for a knee arthrodesis. Currently, the most common indication for knee arthrodesis is an unreconstructable knee following an infection at the site of knee arthroplasty.<sup>[2]</sup> Arthrodesis is indicated also, when there are extensor mechanism disruption, poor bone stock, poor soft tissue envelope, young active patient and recalcitrant infection after revision arthroplasty.<sup>[3]</sup> Arthrodesis by internal fixation either by a plate or an intramedullary nail provides rigid fixation. Intramedullary nailing has the advantage of allowing early weight bearing, and has a high rate of fusion ranging from 88% to 100%.<sup>[4]</sup> But it has the disadvantage that it should be applied only after the infection has been successfully treated which may take up to 40 weeks, and still it carries the risk of dissemination of latent infection.<sup>[5]</sup> On the other hand, external fixation offers possible progressive adjustment to stimulate the bony fusion and to correct malalignment, and there is a considerably lower risk of intramedullary dissemination of the infection, and easy removal of the hardware is possible.<sup>[6]</sup> The purpose of this study is to describe the surgical technique used for arthrodesis of the knee by using uniplanar external fixators.

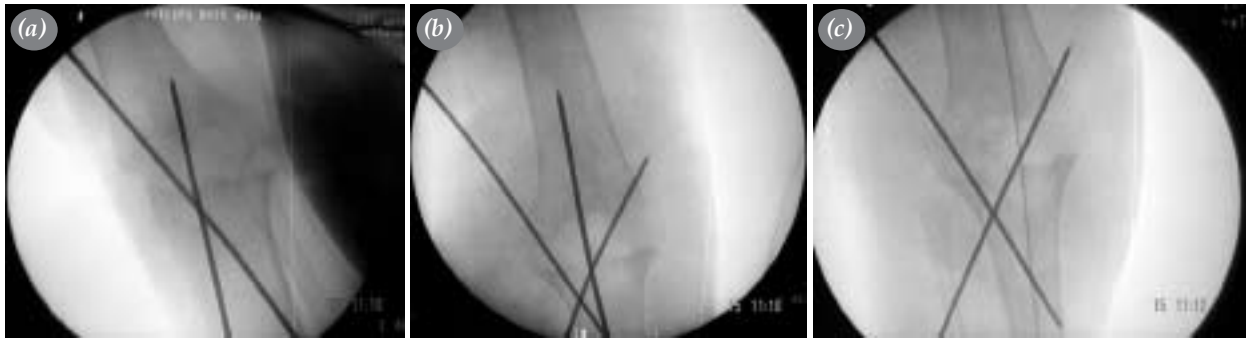
### Patients and methods

Eleven patients, who underwent knee arthrodesis using monolateral external fixator between 1999 and 2005, were evaluated retrospectively. The average age of the patients at the time of surgery was 60 years (range 29-75 years). There were 4 men and 7 women. Average follow up was 28 months (range 7-69 months) (Table I). Indications for knee arthrodesis included complications from septic knee arthritis (4 patients), septic total knee arthroplasty (6 patients), and infected tumor prosthesis for synovial sarcoma in the knee joint (1 patient). We had 8 patients with active knee infection. The six patients with infected total knee arthroplasty had undergone debridement, and application of antibiotic impregnated cement spacers 6 weeks prior to arthrodesis. One patient from the septic arthritis group underwent debridement prior to arthrodesis because of active infection. The 8th pati-

ent who had vague signs of infection caused by low virulent microorganism, was treated by one-stage arthrodesis. In patients who underwent two-staged procedures, multiple samples were obtained from the knee during debridement for culture and antibiogram. Patients were given antibiotics according to the results of culture and antibiogram for an average of six weeks, also patients were followed by laboratory investigations to be sure of remission of infection before the second operation. Methiciline resistant staphylococcus aureus infection in 6 patients was treated with Teicoplanine (2 x 400 mg IV), and Proteus infection in one patient was treated with Cefoperazone (2 x 1 gr IV). In the remaining 3 patients there were no clinical or laboratory evidences of active infection, and the results of culture and antibiogram from samples obtained during arthrodesis were all negative. 2 patients had predisposing factors for infections which are history of open fracture in the proximal tibia, and rheumatoid arthritis respectively.



**Figure 1.**(a) Removal of cement spacer. (b) Filling bone defects by antibiotic loaded demineralized bone matrix.

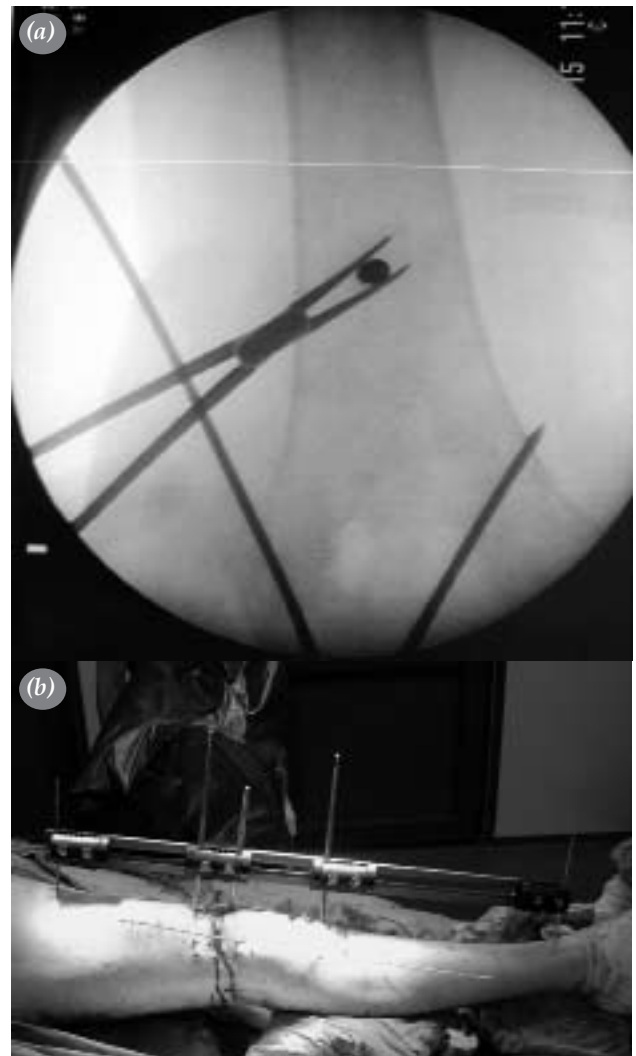


**Figure 2.** (a, b) Temporary fixation of the position of knee arthrodesis by two crossed K wires. (c) Checking the mechanical axis of the limb using electrocautery cord stretched from the center of the femoral head to the center of the ankle joint.

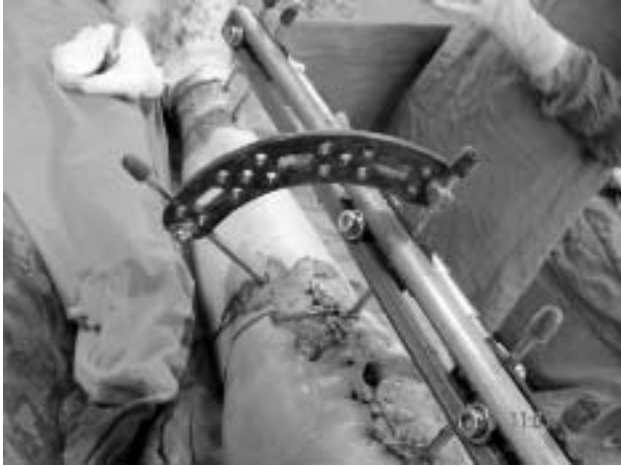### Surgical technique

In all patients the procedures were carried out through previously utilized anterior approaches. In patients who underwent two-staged procedure, the first stage was to remove the infected implant (if present), all infected soft tissue and bone, and application of antibiotic impregnated cement spacer. Culture specific antibiotics are loaded into the cement. 2000mg Teikoplanin was added per 40gr cement powder routinely in all 6 cases with infected TKR. Multiple samples were taken from the wound for culture and sensitivity, and antibiotics were given for an average of 6 weeks according to the results of culture and antibiogram. Second stage procedure was carried on when there is no laboratory or clinical evidence of active infection checked by the ESR and CRP levels every 2 weeks. The steps of knee arthrodesis are nearly the same in patients undergoing one- or two-staged procedure. Anterior approach is used to remove the skin scar, debridement is carried out to create bleeding surfaces in the surrounding soft tissues. The spacer (if present) is removed (Figure 1a), and the bone ends are prepared to create wide, bleeding surfaces. Resection guides from the instrument of total knee replacement (TKR) are used for preparation of distal femoral and proximal tibial bone ends. Any defects in the opposing bony surfaces are filled by antibiotic loaded demineralized bone matrix (Figure 1b). The position of fusion is maintained in 5-10 degrees of flexion and 5-7 degrees of valgus by application of two crossed K wires under guidance of the image intensifier (Figure 2 a, b) Knee position is checked by doing intraoperative malalignment test using the wire of the electrocautery device (Figure 2c). Once the knee position is stabilized in the desired alignment, the wound is closed before application of the external fixator, using monofilamentous surgical threads (prolene) in order to decrease the

risk of infection. Application of the external fixator is started in the sagittal plane. Hydroxyapatite coated Schanz screws of 6 mm diameter are used. The first



**Figure 3.**(a) Application of the first Schanz screw into the central part of the distal femur in the frontal plane. (b) Temporary fixation of the position of the fixator while applying the Schanz screws by using Steinmann pins in the most proximal and distal holes of the fixator clamps.



**Figure 4.** Schanz screw applied to the medial surface of the proximal one third of the tibia and connected to the frame of the external fixator by an arch from the Ilizarov system.

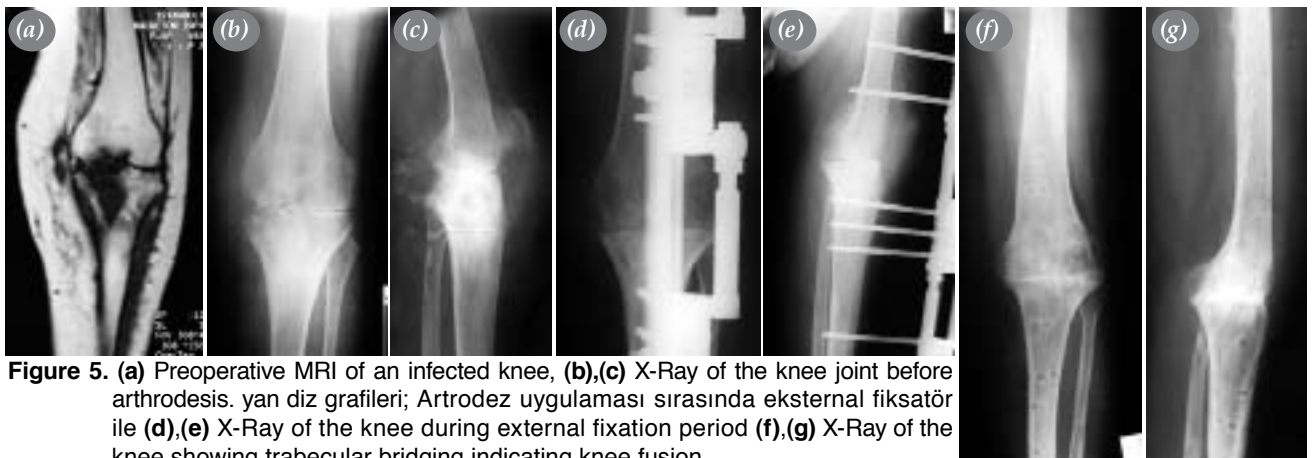
Schanz screw is applied in the distal part of the femur, it should be centralized to the bone in the frontal plane (Figure 3a), and perpendicular to the anatomical axis of the femur in the sagittal plane. The frame of the external fixator is connected to the Schanz screw, with temporary application of two Steinmann pins to the most proximal and most distal holes in the clamps of the fixator to maintain the alignment of the fixator during application of the rest of the Schanz screws (Figure 3b). Generally four Schanz screws are applied in each bone segment. If there is marked osteoporosis or bone loss, then another external fixator is applied in the frontal plane, with two Schanz screws in each bone segment to obtain stable fixation. Application of a Schanz screw medially in the frontal plane to the proximal one third of the tibia, and connecting it to the fixator using an arch or a plate from the Ilizarov system (Figure 4) can also increase the stability of the

fixation when needed. The advantages of this modification is creation of multiplanar fixation, and stable fixation of the proximal tibia by applying a Schanz screw in the center of the bone in the frontal plane. Once the frame is applied, the K wires are removed, and intraoperative compression of the bone ends is done under guidance of image intensifier. Postoperative compression is carried on by the external fixator at a rate of one quarter of 1 mm every 12 hours for one week only. The patient is mobilized on the second day postoperatively by using crutches.

Preoperative magnetic resonance imaging (MRI) shows bone infection. Preoperative X-rays, X-Rays during external fixation have been documented. Postoperative radiography were evaluated for evidence of bony fusion (Figure 5). This was detected by trabecular bridging between the tibia and femur. Radiographic evidence of fusion coupled with no evidence of motion on clinical examination after removal of the fixator were the criteria for successful arthrodesis.

## Results

Consolidation was achieved in all patients after a mean external fixation time of 8 months (range 5-12 months). After removal of the frame, patients were instructed to wear a knee brace for 3 months followed by assisted walking using canes for another month. At the end of the follow-up all patients could walk without walking aids, except patient no 6 who had a marked shortening after arthrodesis. In eight patients infection was completely eradicated with no evidence of recurrence during follow up period. The position of the arthrodesis displayed a mean flexion of 7.8 degrees (range 0-12), and a mean valgus of 7.1 (range 4-12) degrees. Biplanar fixation was used in



**Figure 5.** (a) Preoperative MRI of an infected knee, (b),(c) X-Ray of the knee joint before arthrodesis. (d),(e) X-Ray of the knee during external fixation period (f),(g) X-Ray of the knee showing trabecular bridging indicating knee fusion.

four patients, while uniplanar fixation was used in 7. The decision to use a biplanar fixation was taken when there was poor bone condition either marked osteoporosis or marked bone loss. In patient no 2, after infection was controlled by debridement and antibiotic impregnated cement spacer, long intramedullary nail was applied in association with the external fixators, and lengthening over nail was carried on, at the same time of arthrodesis, for the treatment of preoperative shortening of 6 cm. After restoration of the limb length with radiological evidence of successful arthrodesis, external fixators were removed, and the nail was locked. We intended to leave this patient with 1 cm shortening so that she can easily elevate her foot during swing phase of walking. One patient had intertrochanteric fracture of femur, after she accidentally had fallen down during transportation to the operation room. Therefore the external fixator was modified to fix the fracture as well (6mm half pin). An additional angled clamp was added to the rail to insert Schanz screws fixing the intertrochanteric fracture. Follow-up radiography showed union of the fracture with successful fusion, after seven months. The patient had only 3 cm shortening, and could walk with no difficulties using shoe elevation. This patient died after 34 months from unrelated cause (myocardial infarction). The patient with a history of infected tumor prosthesis had a marked shortening (15 cm). After successful arthrodesis of his knee, he underwent limb lengthening procedure by Ilizarov fixator for the tibia, and Orthofix external fixator for the femur. This shortening is caused by wide tumor resection procedure, so we do not consider it as a complication of the knee arthrodesis. One patient had 3cm shortening at the end of the treatment and received shoe lift and could walk without assistive device. In the remaining patients the average postoperative shortening was 1.38cm (range 1-2cm). According to the Paley complication classification<sup>[7]</sup>, problems occurred in 5 patients in the form of pin tract infection which were treated by oral antibiotics and local care of site of infection.

## Discussion

The indication for knee arthrodesis in this study were primary infectious of origin. 100% of the patients in this study achieved successful fusion and were able to function as community ambulator. We contribute this high fusion rate to the surgical technique, and the site of application of the external fixator.

Maximum bone contact and apposition are extremely important to achieve knee fusion.<sup>[8,9]</sup> Charnley<sup>[11]</sup> believed the success of 99% (169) of the 171 arthrodesis in his patients was due to two perfectly coapted surfaces of cancellous bone, with intact circulation. Hageman et al<sup>[10]</sup> believed that the most important factor for a successful fusion was good bone contact.

We achieved wide bony contact by preparing the distal femoral, and the proximal tibial surfaces using a tibial resection guide from TKR instruments. Stability in the plane of flexion and extension is difficult to achieve by means of coronal compression clamps alone<sup>[11]</sup>, so we used to apply the fixator anteriorly to get maximum stability in the sagittal plane, we also apply another fixator in the coronal plane when there is poor bone condition (either marked bone loss or osteoporosis). The mean knee flexion was 7.8 degrees, while the mean valgus angulation was 7.1 degrees. Five to seven degrees of valgus have been proposed as the ideal frontal alignment<sup>[12]</sup>, and this was easily obtained by the external fixator. Six of the eight patients with active infection underwent two-staged procedure in which debridement, and application of antibiotic impregnated cement was done as the first stage followed by arthrodesis as the second stage after the infection had been eradicated (average 6 weeks). We believe that two-staged procedure in presence of active infection provides the best chance for successful fusion, this supported by two studies which clearly show that if the infection was treated successfully before the arthrodesis was attempted, there was a significant increase in the chances of a successful fusion.<sup>[13,14]</sup> External fixation was used in one patient to correct preoperative shortening of 6 cm by lengthening over nail, it was also used in patient to fix associated intertrochanteric fracture of femur. We consider this as one of the advantages of the use of external fixation, that it can be used to correct other associated problems. Complications occurred only 5 patients in the form of superficial pin tract infection, which resolved completely with oral antibiotics, and local care of pin site, also patient suffered from marked shortening (15cm), as a result of tumor resection, and repeated previous debridement. After removal of the fixators, this patient underwent simultaneous lengthening for femur and tibia using Orthofix and Ilizarov fixators respectively. Although arthrodesis by intramedullary nail had had a high fusion rate up to 95%, and had allowed early weight bearing<sup>[12,15]</sup>, it had many disad-

vantages including the risk of infection dissemination, technical difficulty to maintain adequate degrees of flexion, and valgus, long operative duration, large intraoperative blood loss, nail migration, intraoperative fracture, and inability to maintain postoperative compression.<sup>[5,16,18]</sup> Nichols et al<sup>[19]</sup> studied the use of dual plates to achieve knee arthrodesis, a fusion rate of 100% was achieved in 11 patients. The authors suggested avoiding this technique if gross or acute infection was present.<sup>[19]</sup> More data regarding the effectiveness of this technique are needed to determine the place of dual plates in knee arthrodesis.<sup>[20]</sup> On the other hand, arthrodesis by external fixation had the advantages of maintaining compression across the fusion site, ability for adjustment, and much less risk of infection dissemination.<sup>[17]</sup> The use of Ilizarov device in knee arthrodesis, has improved the success rate of fusion by external fixation markedly (93% - 100%).<sup>[21,22]</sup> But also the rate of complications is as high as 80% and 84%, including pin tract infection, bone fracture at pin site, pin loosening and nonunion.<sup>[20,22]</sup> Despite the studies that showed less favourable fusion rates with the use of uniplanar and biplanar external fixators in knee arthrodesis ranging from 58% to 65% respectively,<sup>[23]</sup> we believe that the usage of surgical technique that creates large bony contact area with application of the frame in the sagittal plane for more stability, can markedly improve the results of arthrodesis by external fixation.

## References

1. Charnley J . Arthrodesis of the knee. *Clin Orthop Relat Res* 1960;(18):37-42.
2. Hanssen AD, Trousdale RT, Osmon DR. Patient outcome with reinfection following reimplantation for the infected total knee arthroplasty. *Clin Orthop Relat Res* 1995;(321):55-67.
3. Bose WJ, Gearen PF, Randall JC, Petty W. Long-term outcome of 42 knees with chronic infection after total knee arthroplasty. *Clin Orthop Relat Res* 1995;(319):285-96.
4. Arroyo JS, Garvin KL, Neff JR. Arthrodesis of the knee with a modular titanium intramedullary nail. *J Bone Joint Surg [Am]* 1997;79:26-35.
5. Vlasak R, Gearen PF, Petty W. Knee arthrodesis in the treatment of failed total knee replacement. *Clin Orthop Relat Res* 1995;(321):138-44.
6. Manzotti A, Pullen C, Deromedis B, Catagni MA. Knee arthrodesis after infected total knee arthroplasty using the Ilizarov method. *Clin Orthop Relat Res* 2001;(389):143-9.
7. Paley D. Problems, obstacles, and complications of limb lengthening by the Ilizarov technique. *Clin Orthop Relat Res* 1990;(250):81-104.
8. Rand JA, Bryan RS, Chao EY. Failed total knee arthroplasty treated by arthrodesis of the knee using the Ace-Fischer apparatus. *J Bone Joint Surg [Am]* 1987;69:39-45.
9. Woods GW, Lionberger DR, Tullos HS. Failed total knee arthroplasty. Revision and arthrodesis for infection and noninfectious complications. *Clin Orthop Relat Res* 1983;(173):184-90.
10. Hagemann WF, Woods GW, Tullos HS. Arthrodesis in failed total knee replacement. *J Bone Joint Surg [Am]* 1978; 60:790-4.
11. Fidler MW. Knee arthrodesis following prosthesis removal. Use of the Wagner apparatus. *J Bone Joint Surg [Br]* 1983;65:29-31.
12. Puranen J, Kortelainen P, Jalovaara P. Arthrodesis of the knee with intramedullary nail fixation. *J Bone Joint Surg [Am]* 1990;72:433-42.
13. Knutson K, Hovelius L, Lindstrand A, Lidgren L. Arthrodesis after failed knee arthroplasty. A nationwide multicenter investigation of 91 cases. *Clin Orthop Relat Res* 1984;(191):202-11.
14. Bengtson S, Knutson K. The infected knee arthroplasty. A 6-year follow-up of 357 cases. *Acta Orthop Scand* 1991; 62:301-11.
15. Donley BG, Matthews LS, Kaufer H. Arthrodesis of the knee with an intramedullary nail. *J Bone Joint Surg [Am]* 1991;73:907-13.
16. Damron TA, McBeath AA. Arthrodesis following failed total knee arthroplasty: comprehensive review and meta-analysis of recent literature. *Orthopedics* 1995;18:361-8.
17. Rand JA. Alternatives to reimplantation for salvage of the total knee arthroplasty complicated by infection. *J Bone Joint Surg [Am]* 1993;75:282-9.
18. Wilde AH, Stearns KL. Intramedullary fixation for arthrodesis of the knee after infected total knee arthroplasty. *Clin Orthop Relat Res* 1989;(248):87-92.
19. Nichols SJ, Landon GC, Tullos HS. Arthrodesis with dual plates after failed total knee arthroplasty. *J Bone Joint Surg [Am]* 1991;73:1020-4.
20. Garberina MJ, Fitch RD, Hoffmann ED, Hardaker WT, Vail TP, Scully SP. Knee arthrodesis with circular external fixation. *Clin Orthop Relat Res* 2001;(382):168-78.
21. David R, Shtarker H, Horesh Z, Tsur A, Soudry M. Arthrodesis with the Ilizarov device after failed knee arthroplasty. *Orthopedics* 2001;24:33-6.
22. Oostenbroek HJ, van Roermund PM. Arthrodesis of the knee after an infected arthroplasty using the Ilizarov method. *J Bone Joint Surg [Br]* 2001;83:50-4.
23. Hak DJ, Lieberman JR, Finerman GA. Single plane and biplane external fixators for knee arthrodesis. *Clin Orthop Relat Res* 1995;(316):134-44.