

The results of digital replantations at the level of the distal interphalangeal joint and the distal phalanx

Distal interfalangeal eklem ve distal falanks seviyesindeki replantasyon sonuçları

Ismail Bulent OZCELİK,¹ Husrev PURISA,¹ Ilker SEZER,¹ Berkan MERSA,¹ Atakan AYDIN²

¹Ist-El Hand Surgery, Microsurgery, and Rehabilitation Group
(TEM Hospital Hand Surgery Department - Gaziosmanpaşa Hospital Hand Surgery Department);
²Department of Plastic and Reconstructive Surgery, İstanbul University İstanbul Medical Faculty

Amaç: Distal uç amputasyonlarında uygulanan replantasyonlar geriye dönük olarak değerlendirildi.

Çalışma planı: Distal interfalangeal eklem distal seviyesinde total amputasyon gelişen 82 hastanın (75 erkek, 7 kadın; ort. yaş 29; dağılım 10-52) 98 parmağına uygulanan replantasyonlar incelendi. Tamai sınıflamasına göre amputasyonların 58'i zon 1, 40'ı zon 2'de idi. Yetmiş yedi (%93.9) hasta digital blok anestezisi altında ameliyat edildi. Kemik fiksasyonunu takiben arter anastomozu ve mümkün olan olgularda ven anastomozu ve nörorafi yapıldı. Ven anastomozu yapılamayan veya anastomoz yapılmasına karşın venöz yetmezlik oluşan olgularda tırnak yatağına iğneyle açılan delikler üzerine heparinize gaz konarak iki saatte bir heparin uygulandı. Hastaların fonksiyonel durumu ve kozmetik açıdan memnuniyeti değerlendirildi. Ortalama takip süresi 16 aydı (dağılım 3-46 ay).

Sonuçlar: Altmış replantasyon (%61.2) başarılı, 38 replantasyon (%38.8) başarısız bulundu. Başarılı sonuç alınan olgularda, tırnağın ve parmak uzunluğunun korunması nedeniyle kozmetik olarak tatmin edici görünüm sağlandı; distal interfalangeal eklemi korunan olgularda fonksiyonel açıdan tatminkar sonuçlar alındı. Zon 1 amputasyonlardaki başarı oranının (%74.1) zon 2 amputasyonlara (%42.5) göre daha yüksek olduğu gözlemlendi.

Çıkarımlar: Distal uç replantasyonları, teknik zorluklara karşın görünüm ve fonksiyonel açıdan tatmin edici sonuçlar verebilmektedir.

Anahtar sözcükler: Travmatik amputasyon/cerrahi; parmak yaralanması/cerrahi; mikrocerrahi/yöntem; replantasyon.

Objectives: We retrospectively evaluated replantations performed for distal amputations.

Methods: The study included 82 patients (75 males, 7 females; mean age 29 years; range 10 to 52 years) who underwent replantations distal to the distal interphalangeal joint for a total of 98 amputations. According to the Tamai classification, there were 58 zone 1 and 40 zone 2 amputations. Local digital anesthesia was used in 77 patients (93.9%). Arterial anastomosis was accomplished after bone fixation, and venous anastomosis and nerve repair were performed whenever possible. When venous anastomosis was not possible or in case of venous insufficiency, venous decompression was performed with heparinized gauze placed on the bleeding nail matrix. Functional results and the degree of patients' satisfaction with the cosmetic outcome were evaluated. The mean follow-up was 16 months (range 3 to 46 months).

Results: Replantation was successful in 60 amputations (61.2%) and unsuccessful in 38 cases (38.8%). In successful cases, cosmetic results were satisfactory due to the preservation of the nail and finger length. Functional results were satisfactory in cases in which the distal interphalangeal joint could be preserved. Replantations for zone 1 amputations (74.1%) yielded better results than those performed for zone 2 amputations (42.5%).

Conclusion: Despite technical difficulties, replantations for distal finger amputations can provide satisfactory functional and cosmetic results.

Key words: Amputation, traumatic/surgery; finger injuries/surgery; microsurgery/methods; replantation.

Due to the small size of the arteries and as well as venous problems, replantation of amputations distal to the distal interphalangeal (DIP) joint is technically difficult. The advances in microvascular surgery techniques have made distal replantations possible.^[1,2] In this study, replantations carried out in amputations distal to the distal interphalangeal (DIP) joint were retrospectively evaluated.

Patients and methods

Between 2000-2004, 98 replantations were carried out on 82 patients (75 males, 7 females), with mean age 29 (10-52). Total amputations distal to the DIP joint level were taken into the evaluation. Subtotal amputations were not included in the study. Twelve patients underwent 2, and 2 patients underwent 3 digit replantations. The injury occurred on the right hand in 45 (54.9%), and left in 37 (45.1% patients). The injured finger was the thumb in 8 (8.2%), second finger in 35(35.7%), third finger in 35 (35.7%), fourth finger in 16 (16.3%) fifth finger in 7 (7.1%). The distal tip amputations were classified according to the Tamai classification (1,3-6). According to this, 58 (59.2%) of the amputations were in Zone 1, and 40 (40.8%) in Zone 2. Prior to the admission of the patient to the operating room, the amputated part was examined for the availability of the vascular structures for replantation. The operation was carried out under general anesthesia in 2 patients (2.4%), axillary block in 3 (3.7%), and digital block in 77 (93.9%). The patients received 500 cc Rheomacrodex infusion adjusted to be infused over 24 hours, low molecular weight heparin, and antibiotic prophylaxis with cephazoline sodium. No osteosynthesis was made 12 of the Zone 1 injuries. In Zone 2 amputations, arthrodesis was made in 18 amputations in which the DIP joint was severely damaged, whereas minimal osteosynthesis with K wires was made in the remaining. In cases with nail bed injury, the nail bed was repaired with 6/0 chromic catgut. After a portion of the skin was sutured, the corresponding arteries in the amputate and stump were prepared, and anastomosed with 10/0 Ethilon sutures. Four fingers in Zone 2 group had both digital arteries repaired. Vein grafts were used in 5 fingers, and one finger received artery graft harvested from the contralateral side. In Zone 1 amputations, one artery was repaired, and no artery or vein grafts were used. Due to the small size of the vessels, the number of anastomotic sutures were

less, using 4-5 suture per anastomosis. Venous repair was not possible in 12 patients with injury in Zone 2. In the distal interphalangeal joint or distal to it, the volar veins were preferred over the dorsal, due to their larger diameter. In cases in which venous anastomosis was not possible, or cases with venous drainage insufficiency despite venous repair, the nailbed was punctured with needles and was covered with heparinized gauze, which was replaced every two hours. Leeches were applied in cases which did not respond to the above stated methods. Twelve amputations in Zone 2, and 3 amputations in Zone 1 had one nerve repair, and 5 amputations in Zone 2 had bilateral nerve repair. The skin was loosely closed. In the postoperative period, the patients received Rheomacrodex 500 cc per 24 hours, low molecular weight heparin, cephazoline sodium and analgesics. Mean length of stay was 5 days. Successful replantations were evaluated with respect to function, and the patients' satisfaction regarding cosmesis were asked. Mean follow up was 16 months (range 3-46 months)

Results

Replantation was successful in 60 fingers (61.2%), and failed in 38 (38.8%). There were 23 (57.5%) failures in Zone 2 replantations. In failed replantation cases, 13 were repaired with cross-finger flap, 24 with stump closure, and 1 with V-Y advancement flap. Postoperative evaluation revealed that all of the 6 patients who had successful replantation with arthrodesis had satisfactory range of motion, and the patients were satisfied with the cosmetic results (Figure 1,2).

Discussion

There are numerous techniques for the treatment of distal tip amputations. Primary repair with or without bony shortening, local flaps, regional flaps, free flaps, neurovascular island flaps, composite grafts, and skin grafts. These techniques however, may have complications such as unesthetic appearance, shortness of the finger, persistent pain, hypersensitivity, cold intolerance, sensory loss, hypesthesia, paresthesia, soft tissue atrophy, absence of nail, nail deformity, decreased range of motion, decreased power grip, Some of the above techniques require a second stage operation. Donor site problems and cosmetic problems may occur in the donor finger.^[2,4,5,7] In successful distal tip replantations, the

finger length and the nail was preserved, and in most patients the preservation of the DIP joint led to satisfactory functional results. However, as the amputation level goes more distally, the vessel diameter decreases, rendering the anastomosis technically more difficult.^[1,2,4,5]

The most common classification used in the distal phalanx amputations is the Tamai classification.^[1,3-6] In this classification, the distal phalanx is separated into two. The distal part (Zone 1) is from the nail bed to the tip; and the proximal part (Zone 2) is from the nail bed to the DIP joint. There are 3 main arterial arches in the finger. Distal and proximal arches are related to the proximal and distal cruciate ligament arms. The distal arch is immediately distal to the flexor digitorum superficialis insertion. The digital artery diameter is between 0.4-0.7mm at the basis of the distal phalanx. The diam-

eter of the terminal vessels are between 0.3-0.7mm.^[8] At the level of the finger pulp, the distal central artery is the most suitable vessel for microvascular surgery.^[5] At the level of the proximal phalanx, the dorsal veins are larger compared to the volar veins, whereas at the DIP joint level the volar veins are larger than the dorsal veins.^[9]

Hirase^[10] classified distal tip replantations and determined the treatment. He divided the nail bed level into three parts. The first part is the fingertip region, where the digital artery gives the terminal branches. Composite grafting is suggested for amputations at this level. The second part includes the distal palmar arch of the digital artery. To avoid interference with venous drainage through the medullary cavity, bony fixation is not recommended at this level. Central digital artery anastomosis is recommended, however no treatment is suggested

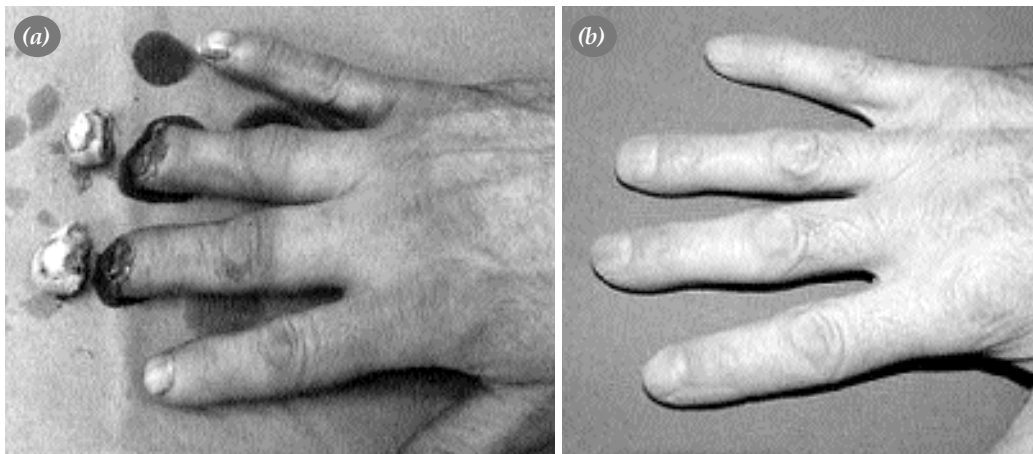


Figure 1. Zone I amputation of third and fourth finger of 26 year old male patient due to machinery-tool in workplace. The view before (a) and 16 months after the operation (b).

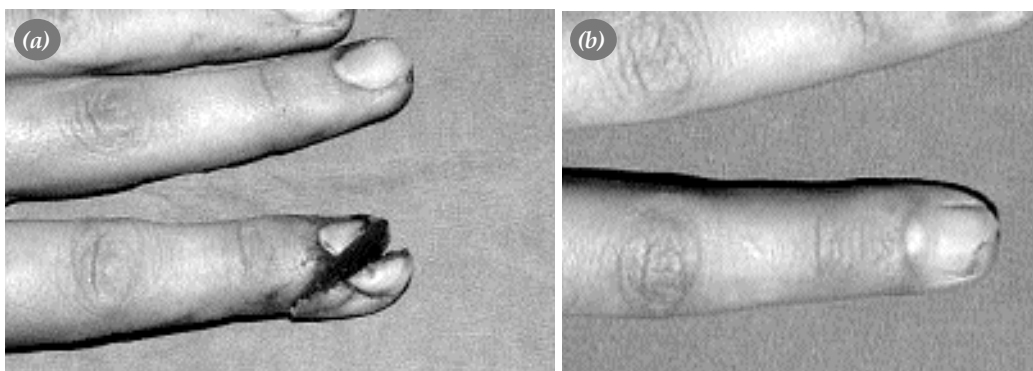


Figure 2. Zone I oblique amputation of second finger of 24 year old male patient due to accident in workplace. The view before (a) and 8 months after the operation (b).

for venous drainage. The third part is the proximal aspect of the nail bed. Drainage in replantations at this level are done with the application of heparinized gauze to the nailbed or leeches.

Koshima et al.^[10] reported the arteriovenous anastomosis technique to solve the problems of the arterial system and venous drainage. Yamano^[11] used uricolysis during the first 7 days, followed by heparinized gauze application and heparin and saline drips to a fish mouth incision made in the pulp. Akyurek et al.^[5] in their series of 21 patients with amputation at the distal nail bed level, reported that they performed single artery anastomosis, and no venous or nerve anastomosis. In their study, venous drainage was achieved with only bloodletting, and the success rate was 76%. In our study, success rate of Zone 1 amputations (74.1%) were superior to Zone 2 amputations (42.5%). We believe that the greater failure rate in Zone 2 replantations is due to venous insufficiency. At this level, the dorsal veins are too small, and the volar veins inadequate. Venous drainage through the nailbed may not suffice. In Zone 2 replantation, effort was shown to make at least one or two vein anastomosis. As in Zone 2, the greatest problem in Zone 1 is venous drainage. In Zone 1 replantations, 8 (14%) had one venous anastomosis on the volar aspect. Venous repair may not be possible at this level due to the small diameter of the veins at this level and the immobility of the skin and nailbed on the dorsal side. Venous drainage was accomplished by the application of heparinized gauze every two hours to the sites punctured with needles. Leech therapy was applied in conditions where the above treatment was insufficient. These two treatments for venous drainage gave successful results. One patient who underwent two digit replantation and external drainage required blood transfusion due to significant bleeding. Anticoagulation in this patient was ceased earlier when compared to other patients.

In Zone 1 level replantations without osteosynthesis, 10 of the 12 replantations (83.3%) were successful. In these 12 amputations, the nailbed was repaired first, followed by anastomosis of the central artery. These cases had no venous repair. Although arterial anastomosis distal to the nailbed was difficult, it was completed with 4 or 5 sutures using 10/0 suture material.

In replantation cases where severe trauma necessitated arthodesis of the distal interphalangeal joint, there were 12 failures among a total of 18 replantations, with a failure rate of 66.7%. It was seen that crush injuries that cause significant bone injury lowered the success rate. Five of the thumb replantations (62.5%), and 16 (45.7%) of index finger replantations failed. Due to the significance of the first two fingers on hand function, priority was given to replant these digits, even in severe injuries, which lowered the replantation indications in these fingers.

Four of the 5 replantations that had artery repair with vein grafts failed. Vein grafts were used in Zone 2 injuries of the second and third fingers.

In distal tip replantations, an acceptable sensory recovery is possible, even when the digital nerve is not repaired.^[5-12] Dubert et al.^[2] Reported that there is no significant sensory loss in distal tip replantations without nerve repair.

In amputations distal to the lunula, blunt trauma or crush injury did not cause a problem in nail growth, as long as the injury did not destroy the germinal matrix. Nail growth disturbances are more common in injuries proximal to the lunula. A portion of the cases had nail deformities. Hook, cleft, hump nail deformities are possible.^[6]

In conclusion, replantations at Zone 1 have higher success rates when compared to Zone 2. Function and appearance are satisfactory in successful replantations at both levels.

References

1. Yamano Y. Replantation of the amputated distal part of the fingers. *J Hand Surg [Am]* 1985;10:211-8.
2. Dubert T, Houimli S, Valenti P, Dinh A. Very distal finger amputations: replantation or "reposition-flap" repair? *J Hand Surg [Br]* 1997;22:353-8.
3. Tamai S. Twenty years' experience of limb replantation-review of 293 upper extremity replants. *J Hand Surg [Am]* 1982;7:549-56.
4. Patradul A, Ngarmukos C, Parkpian V. Distal digital replantations and revascularizations. 237 digits in 192 patients. *J Hand Surg [Br]* 1998;23:578-82.
5. Akyurek M, Safak T, Kecik A. Fingertip replantation at or distal to the nail base: use of the technique of artery-only anastomosis. *Ann Plast Surg* 2001;46:605-12.
6. Nishi G, Shibata Y, Tago K, Kubota M, Suzuki M. Nail regeneration in digits replanted after amputation through the distal phalanx. *J Hand Surg [Am]* 1996;21:229-33.
7. Goldner RD, Stevanovic MV, Nunley JA, Urbaniak JR. Digital replantation at the level of the distal interphalangeal joint and the distal phalanx. *J Hand Surg [Am]* 1989;14(2 Pt 1):214-20.

8. Strauch B, de Moura W. Arterial system of the fingers. *J Hand Surg [Am]* 1990;15:148-54.
9. Smith DO, Oura C, Kimura C, Toshimori K. The distal venous anatomy of the finger. *J Hand Surg [Am]* 1991;16:303-7.
10. Hirase Y. Salvage of fingertip amputated at nail level: new surgical principles and treatments. *Ann Plast Surg* 1997;38:151-7.
11. Koshima I, Soeda S, Moriguchi T, Higaki H, Miyakawa S, Yamasaki M. The use of arteriovenous anastomosis for replantation of the distal phalanx of the fingers. *Plast Reconstr Surg* 1992;89:710-4.
12. Suzuki K, Matsuda M. Digital replantations distal to the distal interphalangeal joint. *J Reconstr Microsurg* 1987;3:291-5.