



Correction of complex lower extremity deformities with the use of the Ilizarov-Taylor spatial frame

Kompleks alt ekstremite deformitelerinin Ilizarov-Taylor uzaysal çerçeve ile düzeltilmesi

Metin KUCUKKAYA, Ozgur KARAKOYUN, Raffi ARMAGAN, Unal KUZGUN

Sisli Etfal Research and Training Hospital, Department of Orthopaedic and Traumatology

Amaç: Bu çalışmada Taylor uzaysal çerçevenin (Smith & Nephew, Memphis, TN, ABD) kompleks alt ekstremite deformitelerinin tedavisindeki etkinliği incelendi.

Çalışma planı: Taylor uzaysal çerçeve (TSF) 25 hastanın (12 kadın, 13 erkek; ort. yaş 17) 29 kemik segmentinde kullanıldı. Uygulama nedenleri, doğuştan deformite (n=12), raşitizm sekeli (n=6), fiz hasarı (n=4), sert psödoartoz (n=3), kötü pozisyonda kaynama (n=3) ve diz septik artrit sekeli (n=1) idi. Uygulamaların 15'i tibia, dokuzu femur, dördü ayak, biri de dize yönelik yapıldı. Beş TSF uygulaması osteomisz, diğerleri osteotomili yapıldı. Altı olguda TSF ile deformite akut olarak düzeltildikten sonra ameliyat sırasında internal osteosentez uygulanarak fiksator çıkartıldı. Akut düzeltme yapılan altı olguda "kronik program" ile, geri kalan olgularda "önce halkalar yöntemi" ile tedrici düzeltme yapıldı. Hastaların takip süresi 8-42 ay arasında (ort. 29 ay) değişmekteydi.

Sonuçlar: Düzeltme uygulanan 13 tibia ve beş femur segmentinde eksternal fiksator süresi ortalama 24.5 hafta (dağılım 18-37 hafta) idi. Bütün olgularda mekanik eksen normal sınırlar içerisine gelene kadar düzeltme yapıldı. Psödoartoz nedeniyle TSF uygulanan üç olgu da dahil, osteotomi yapılan olguların hepsinde tam konsolidasyon elde edildi. Ayak deformitelerinin hepsinde plantigrad ayak elde edildi. Diz fleksiyon kontraktürü ve posterior subluksasyonu osteotomisz olarak düzeltilen bir olguda nüks görüldü.

Çıkarımlar: Veriler doğru hesaplanır ve doğru kullanılırsa, psödoartrozların ve özellikle translasyon ve rotasyon ile komplike olmuş deformitelerin tedavisinde TSF mükemmel düzeltme sağlayabilen güvenli ve pratik bir sistemdir.

Anahtar sözcükler: Eksternal fiksator; femur/abnormallik; hipertrofi; Ilizarov tekniği; osteogenez, distraksiyon/enstrümantasyon; osteotomi/yöntem; tibia/abnormallik.

Objectives: We evaluated the effectiveness of the Taylor spatial frame (Smith & Nephew, Memphis, TN, USA) in the treatment of complex lower extremity deformities.

Methods: The Taylor spatial frame (TSF) was applied to 29 bone segments of 25 patients (12 females, 13 males; mean age 17 years). Indications for the TSF were congenital disorders (n=12), rickets (n=6), physal injuries (n=4), stiff nonunions (n=3), malunions (n=3), and sequela from septic arthritis of the knee (n=1). Applications involved the tibia (n=15), femur (n=9), foot (n=4), and knee (n=1) with (n=24) or without (n=5) osteotomies. Following acute correction with the use of the TSF and internal osteosynthesis by plating or nailing, the fixator was removed in six cases. The chronic mode was used in six cases who underwent acute correction. The remaining deformities were gradually corrected using the "total residual mode". The follow-up period ranged from eight months to 42 months (mean 29 months).

Results: The mean duration of external fixator was 24.5 weeks (range 18 to 37 weeks) in 13 tibial and five femoral segments. In all cases, correction was applied until the mechanical axis reached normal limits. Complete consolidation was achieved in all osteotomized segments, including three cases of nonunion. A plantigrade foot was obtained in all foot deformities. Recurrence was seen in one case in which knee contracture and subluxation were treated with soft tissue distraction without osteotomy.

Conclusion: The Taylor spatial frame is a safe and practical method with excellent results in the treatment of nonunions and deformities complicated especially by translation and rotation providing correct clinical data are derived and used.

Key words: External fixators; femur/abnormalities; hypertrophy; Ilizarov technique; osteogenesis, distraction/instrumentation; osteotomy/methods; tibia/abnormalities.

Limited angular deformities of the lower extremity can be successfully corrected with the Ilizarov distraction method.^[1,2] Ring systems used in classical methods can only correct the deformities in the angulation plan, but do not correct residual translation – rotation deformities outside this plan. Therefore, in the classic Ilizarov deformity correction planning, ring systems providing elongation, angulation, translation and rotation, independent of each other, are used in a specific sequence or simultaneously. In this case, fixator may need modification occasionally throughout the correction of complex deformities. The Taylor spatial frame (TSF) (Smith & Nephew, Memphis, TN, USA) developed by Charles Taylor in 1994, and adhering to Ilizarov principles, can solve many problems encountered with classic circular external fixators.^[3-6] This system uses an external fixator with six telescopic struts attaching two rings to each other and a computer software. A prescription is derived by entering 13 measurements of deformity, dimensions of the strut-ring used and location of TSF on the extremity in the computer software. Software creates a prescription adjusting the rate and direction

of change for the struts' length and composes a virtual hinge system. After the prescription is applied within the planned time, re-planning is possible via the computer software. This study evaluates the results of patients with complex lower extremity deformities who have been treated in our clinic with TSF, and the efficacy of the system.

Patients and method

TSF was utilized in 29 bone segments of 25 patients (12 female, 13 male; mean age 16.8 years) between January 2005 and September 2007 (Figure 1, 2). Reasons for utilization were congenital deformity in bone segment (n=12), sequelea of rickets (n=6), physal damage (n=4), rigid pseudoarthrosis (n=3), malunion (n=3) and sequelea of septic arthritis in the knee (n=1). Fifteen procedures were performed in the tibia, nine in the femur, four in feet and one in the knee joint. Among these procedures, 12 had tibial osteotomy, nine had femoral osteotomy, and three had osteotomy of the feet. Five TSF procedures were performed without an osteotomy. Locked plaque was applied in five of the six cases where the deformity

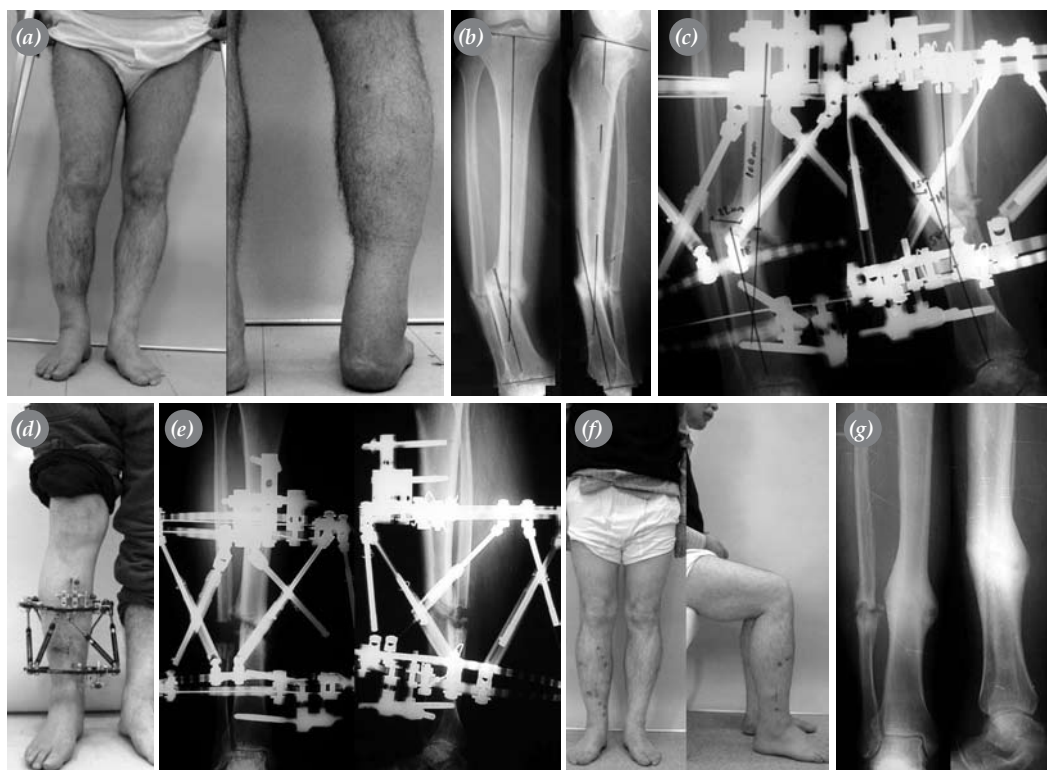


Figure 1. (a,b) Clinical and radiographic appearance of a forty-eight year old patient with a deformity due to malunion. (c) Postoperative early radiograms. (d, e) Clinical and radiographic appearance after the deformity was corrected. (f, g) In the clinical and radiographic images after one year, complete functional and radiographic healing can be observed.

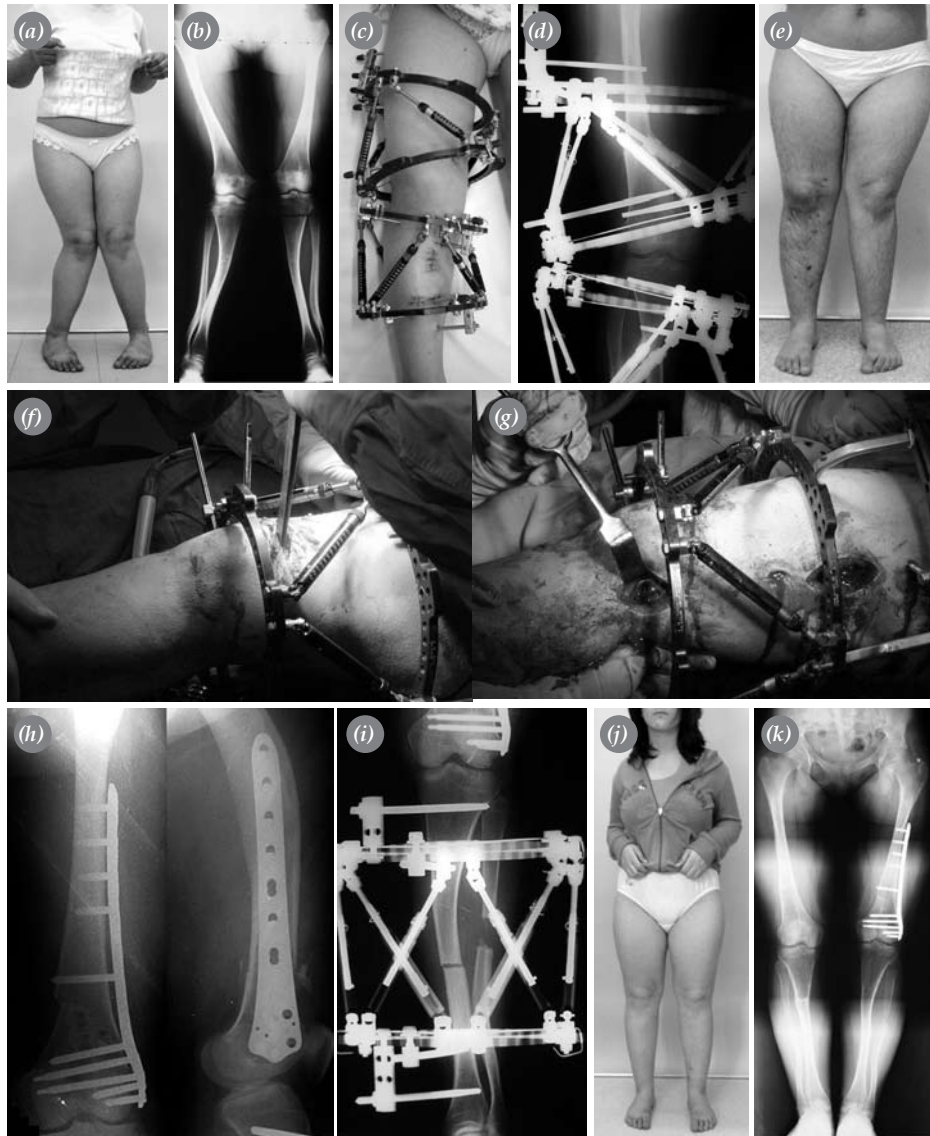


Figure 2.(a, b) Clinical and radiographic appearance of a 13 year old patient with rickets sequelae deformity in both lower extremities. (c, d) Clinical and radiographic appearance of the right extremity postoperatively. (e) Clinical appearance of the right extremity after the completion of treatment. (f, g) Intraoperative images of the femur deformity during TSF assisted locked plaque osteosynthesis. (h, i) Radiograms of the left extremity postoperatively, TSF and the osteotomy line may be seen on the tibia. (j, k) Two years post surgery, all components of the deformities can be seen to be healed clinically and radiographically.

was corrected acutely, and osteosynthesis was performed with an intramedullar nail in one case. Midfoot osteotomy was performed in two of the foot deformity cases, and posterior calcaneal osteotomy in one of the cases, whereas one foot deformity was corrected by soft tissue distraction technique, without an osteotomy.

In three tibial cases where deformity developed due to rigid pseudoarthrosis, deformity was gra-

dually corrected with TSF in two cases following fibular osteotomy; acute correction was performed in one case with locking plate and osteosynthesis. Contracture was corrected while correcting subluxation in one case with flexion contracture of the knee and posterior subluxation. Among cases where fixator assisted osteosynthesis was performed, 4.5 mm titanium locked femoral anatomical plate (LISS-Synthes) (n=2), straight 4.5 mm titanium

locked plate (Synthes) (n=2), and 4.5 mm steel locked femoral anatomical plate (Smith & Nephew) (n=1) were used.

All patients had preoperative standard anterior-posterior, lateral radiographic and ortoroentgenographic measurements taken and deformity parameters were determined with clinical examination findings. In deformities excluding the foot, 15 had only frontal plane, seven had oblique plane and one had only saggital plane deformities. In these cases mean angular deformity was 20.4° (range 0°-40°), rotational deformity was 17.3°

(range 0°-70°), translational deformity was 6.3 mm (range 0-26 mm), and shortness was 10.1 mm (range 0-85 mm). One patient who only had rotational deformity in the femur and tibia, did not have angular deformity.

Patients were operated on a radiolucent table in the supine position. Kirschner wires were placed against the risk of nerve injury, and general anesthesia or epidural anesthesia that does not cause neuromuscular blockade were preferred. In cases where an osteotomy was performed, fibular osteotomy was realized with the application of tourniquet. If tibial osteotomy was to be performed using the gigli technique, tourniquet was released after the gigli saw was passed through and the procedure continued with TSF.

In this procedure three types of correction mode may be preferred.^[6] In the “chronic mode”, the length of six struts are estimated according to pre-surgery radiographic measurements with the help of the computer software and TSF that completely mimics the deformity is installed. In this way, when the TSF struts applied on the patient are at neutral the deformity is corrected. In the “residual mode”, TSF is installed with the patient at neutral position (all struts at equal length), correction is obtained according to the correction prescription prepared by the software and when the deformity is corrected the fixator mimics the deformity. In the “total residual mode” (rings first method), rings are installed in the most suitable position on the extremity for the fixator rings, perpendicular to all segments or parallel to joints. This position is described as the “curved frame on the curved bone”. Later, the deformity is corrected with the prescription prepared with the computer software. When the rings are parallel to each other, correction

is established. However, there is usually some uncorrected deformity with this method, and the remaining deformity is estimated again with the residual mode method, and corrected.

In six cases where the deformity was acutely corrected with TSF and fixated with a plate or intramedullar nail, chronic mode was used. TSF mimicking the deformity was prepared before surgery and performed on the patient and acute correction was obtained based on the prescription; following internal osteosynthesis, TSF was removed before the patient recovered from anesthesia. This fixator used temporarily was not charged to the patient.

In all other patients, first the reference ring was installed perpendicular to the bone segment; in radiographs taken after the surgery, a total of 13 measurements were assessed and the correction prescription was prepared through estimation with the total residual mode. Taking the anatomical structures under risk into consideration, rate of correction was adjusted according to the fibular nerve in valgus deformities surrounding the knee, and posterior neurovascular structures in saggital plane deformities. Correction rate was adjusted in the foot-ankle region according to neurovascular structures and other soft tissues. Correction procedure was started on the fifth day in patients who had osteotomy and on the second day in other patients. Patients were encouraged to bear full weight throughout the treatment. The Taylor spatial frame was removed after total consolidation was obtained with the osteotomies, and after the safe waiting period in cases without an osteotomy.

Results

Patients were followed between 8 and 42 months (mean 28.9 months). In 13 tibial and 5 femoral segments where the deformity was corrected gradually, the external fixator period was 24.5 weeks (range 18-37 weeks). All cases were corrected until obtaining a satisfactory cosmetic result and the mechanical axis was within normal ranges. Complete consolidation was achieved in all cases with an osteotomy. In one case with a two stage osteotomy, there was a 2.5 cm shortening following an elongation of 6 cm. In a 10 year old patient with 5 cm shortening and 18° oblique plane deformity due to physeal damage, there was a 2 cm excess length after elongation and correction. When the patient was followed after one year, another

shortening of 1 cm was detected due to the elongation of the opposite side. All patients were seen to have superficial wire problems, but these were all insignificant and none of these patients required parenteral antibiotic treatment. In one patient where straight titanium locked tibial plate was used, a reduction loss of 3° due to the stretching of the plate was seen in the x-rays taken after the TSF was removed. In four foot deformities plantigrade foot was achieved as a result of the TSF procedure. These patients were protected against the risk of recurrence with a cast or orthosis worn for one year. In the case where the knee flexion contracture and posterior subluxation were corrected, TSF was removed following the recurrence of the contracture; one year later knee arthrodesis was performed.

Discussion

The main problem in the correction of complex deformities with classic circular external fixators is the modifications needed in the fixator for residual deformities that occur. Angulation before correction, shortening, rotation and finally correction of translation deformity is the procedure recommended for minimum modification.^[1] Moreover, in the classic systems, the hinges must be installed perfectly on the patient in order to achieve a complete correction. However, in the TSF procedure, all components of the deformity may be corrected simultaneously, and the correction may be performed to provide the best clinical outcome by observing the rotational problems detected with clinical measurements during patient follow-up. In addition, residual deformities that may occur may be re-programmed to obtain a perfect correction. Correction of the deformity with the minimum repeat of procedure is related with excellent measurement taking and the experience of the surgical team in this subject. Whereas six repeat measurements per patient were required in our initial cases, only one planning was needed to obtain a perfect correction in our recent procedures. The primary problem in hypertrophic pseudoarthroses is the lack of stability in spite of sufficient biological capacity needed for healing. The deformity resulting from these pseudoarthroses may be corrected with the Ilizarov distraction treatment and heal without having to open the pseudoarthrosis line and grafting.^[1,4,7] However, if there are translation and rotation problems in the deformity, correction by classic circular fixators may become very challenging

due to the need for occasional modification of fixator. On the other hand, the Taylor spatial frame can provide perfect anatomical reduction and stability with the help of the computer software in pseudoarthroses with complicated deformities. We performed gradual correction with the Taylor spatial frame and compression on the pseudoarthrosis line in two cases with hypertrophic (rigid) pseudoarthroses and achieved complete healing. The important advantages of TSF in these cases are being a very stable external fixator, correcting all components of the deformity and most importantly, allowing compression on a perpendicular plane to the pseudoarthrosis line. Fixator assisted intramedullar nailing technique is often preferred in the correction of the frontal plane only or sagittal plane only deformities of the femur and tibia.^[8] In recent years, locked plaques are used in the correction of deformities with external fixators.^[9] However, if there is a rotational deformity or locked plaque is going to be used on the femur in more complicated oblique plane deformities, one-sided external fixators are not the ideal technique for correction. The Taylor spatial frame can correct complicated deformities with excellent precision, allowing the use of locked plate or intramedullar while the fixator is still on the patient. While we preferred one-sided external fixators in cases with monoplane simple deformities, we prefer TSF in more complicated deformities or situations where we use locked plate on the femur. The main challenge in this practice is creating the prescription that corrects the deformity through an internet-based software intraoperatively. In order to avoid such a problem, we prepared the TSF and the prescription preoperatively (“chronic mode”) and installed the external fixator. This approach allowed us to rehearse the correction of the deformity and prevented the technical problems we might have encountered during surgery. With the classic Ilizarov distraction method many components of complicated foot deformities may be successfully corrected.^[1,10,11] The Ilizarov method describes hinge systems that can correct rotational deformities, but this system does not appear to benefit hind foot complicated deformities. Our observations in our cases demonstrate that the main advantage of the TSF to the classic Ilizarov method is the correction of hind foot rotational deformities with only one fixator, without the need for a modification in the hinge system. Consequently, TSF is the evolved form of the classic Ilizarov system that utilizes mat-

hematics and a computer software. If data are used correctly in the correction of the deformity, perfect correction is possible. According to our clinical observations, TSF is a very convenient method that can be preferred specifically in the treatment of deformities and pseudoarthroses complicated with translation and rotation.

References

1. Ilizarov GA. The transosseous osteosynthesis: theoretical and clinical aspects of the regeneration and growth of tissue. Berlin: Springer-Verlag; 1992.
2. Köseoğlu E, Yıldız C, Ateşalp AS, Başbozkurt M, Gür E. Treatment of posttraumatic lower limb deformities with the Ilizarov method. [Article in Turkish] *Acta Orthop Traumatol Turc* 2000;34:480-7.
3. Rozbruch SR, Fragomen AT, Ilizarov S. Correction of tibial deformity with use of the Ilizarov-Taylor spatial frame. *J Bone Joint Surg [Am]* 2006;88 Suppl 4:156-74.
4. Rozbruch SR, Helfet DL, Blyakher A. Distraction of hypertrophic nonunion of tibia with deformity using Ilizarov/Taylor Spatial Frame. Report of two cases. *Arch Orthop Trauma Surg* 2002;122:295-8.
5. Rozbruch SR, Pugsley JS, Fragomen AT, Ilizarov S. Repair of tibial nonunions and bone defects with the Taylor Spatial Frame. *J Orthop Trauma* 2008;22:88-95.
6. Taylor JC. Six-axis deformity analysis and correction. In: Paley D, Herzenberg JE, editors. *Principles of deformity correction*. Berlin: Springer-Verlag; 2002. p. 411-36.
7. Kocaoğlu M, Eralp L, Şen C, Çakmak M, Dinçyürek H, Göksan SB. Management of stiff hypertrophic nonunions by distraction osteogenesis: a report of 16 cases. *J Orthop Trauma* 2003;17:543-8.
8. Paley D, Herzenberg JE, Bor N. Fixator-assisted nailing of femoral and tibial deformities. *Tech Orthop* 1997; 12:260-75.
9. Rogers MJ, McFadyen I, Livingstone JA, Monsell F, Jackson M, Atkins RM. Computer hexapod assisted orthopaedic surgery (CHAOS) in the correction of long bone fracture and deformity. *J Orthop Trauma* 2007;21:337-42.
10. Küçükaya M, Kabukçuoğlu Y, Kuzgun Ü. Management of the neuromuscular foot deformities with the Ilizarov method. *Foot Ankle Int* 2002;23:135-41.
11. Paley D. Principles of foot deformity corrections. In: Gould JS, editor. *Operative foot surgery*. Philadelphia: W.B. Saunders; 1994. p. 476-514.