



Bilateral anterior shoulder dislocation in two cases due to housework accidents

Ev kazası sonucu iki hastada iki taraflı anterior omuz çıkığı

Tughan KALKAN, İsmail DEMIRKALE, Ali OCGUDER, Serhan UNLU, Murat BOZKURT

Diskapi Yıldırım Beyazıt Education and Training Hospital 3 rd Orthopaedics and Traumatology Clinic

Bu yazıda, ev kazası sonucu eşzamanlı iki taraflı anterior omuz çıkığı gelişen iki kadın hasta (yaş 64 ve 65) sunuldu. Her iki hastada da çıkıklar, sandalye üzerinde perde asmakta iken dengenin bozulması ve düşmemek için her iki el ile tutunma çabası sırasında meydana gelmişti. Uzun süre asılı kalma sonucu bir hastada geçici brakiyal pleksus paralizisi gelişti. Omuz çıkıkları kapalı redüksiyon ile başarılı şekilde tedavi edildi. Hastaların 1.5 yıllık takiplerinde eklem hareket açıklığında azalma ya da kuvvet kaybı görülmedi, her iki omuz da stabil olarak değerlendirildi. Ev kazaları, özellikle denge sorunu olan yaşlı hastalarda iki taraflı anterior omuz çıkıklarına neden olabilir.

Anahtar sözcükler: Omuz çıkığı/fizyopatoloji/tedavi; omuz eklemi/fizyopatoloji.

We present two cases of simultaneous bilateral anterior shoulder dislocations caused by housework accidents. Both patients (females, aged 64 and 65 years) sustained injuries when they lost balance and tried to grab something to prevent falling during hanging curtains on a chair. One patient developed brachial plexus palsy due to prolonged hanging position. Shoulder dislocations were successfully reduced by closed reduction. Both patients were followed-up for 1.5 years, during which no decrease in range of motion, strength loss, or shoulder instability were seen. Housework accidents can lead to bilateral shoulder dislocations especially in elderly patients with balance problems.

Key words: Shoulder dislocation/physiopathology/therapy; shoulder joint/physiopathology.

Shoulder dislocations are the most common major joint dislocations encountered in the emergency departments and Neer fractures can accompany with dislocations.^[1,2] At the advanced age, structural collagen alterations can induce both dislocations and accompanying rotator cuff tears. There is uncertainty whether shoulder instability leads to rotator cuff tear. Rotator cuff is a serious stabilizer of the shoulder joint. Eventual capsular lesions with rotator cuff tears should be evaluated at older patients in whom a painful abduction persists after reduction of dislocation.^[4]

In the present report, we present two cases of simultaneous bilateral anterior shoulder dislocations at two elderly women caused by an unbalanced position

when they were trying to grab something to prevent falling.

Case report

Case I- A 65-years-old woman was admitted to emergency department with pain and restriction of movement on both sides of her shoulder. Injury was occurred while she was hanging on curtains over the windows and she had lost her balance by the sliden- ce of the chair. To protect herself from falling, she had grabbed and hanged on a bar on the window with her two hands. Physical examination showed bilateral squaring of her shoulders (epaulet sign) without evidence of peripheral motor, sensory and vascular deficit and both two shoulders were in fixed abduc-

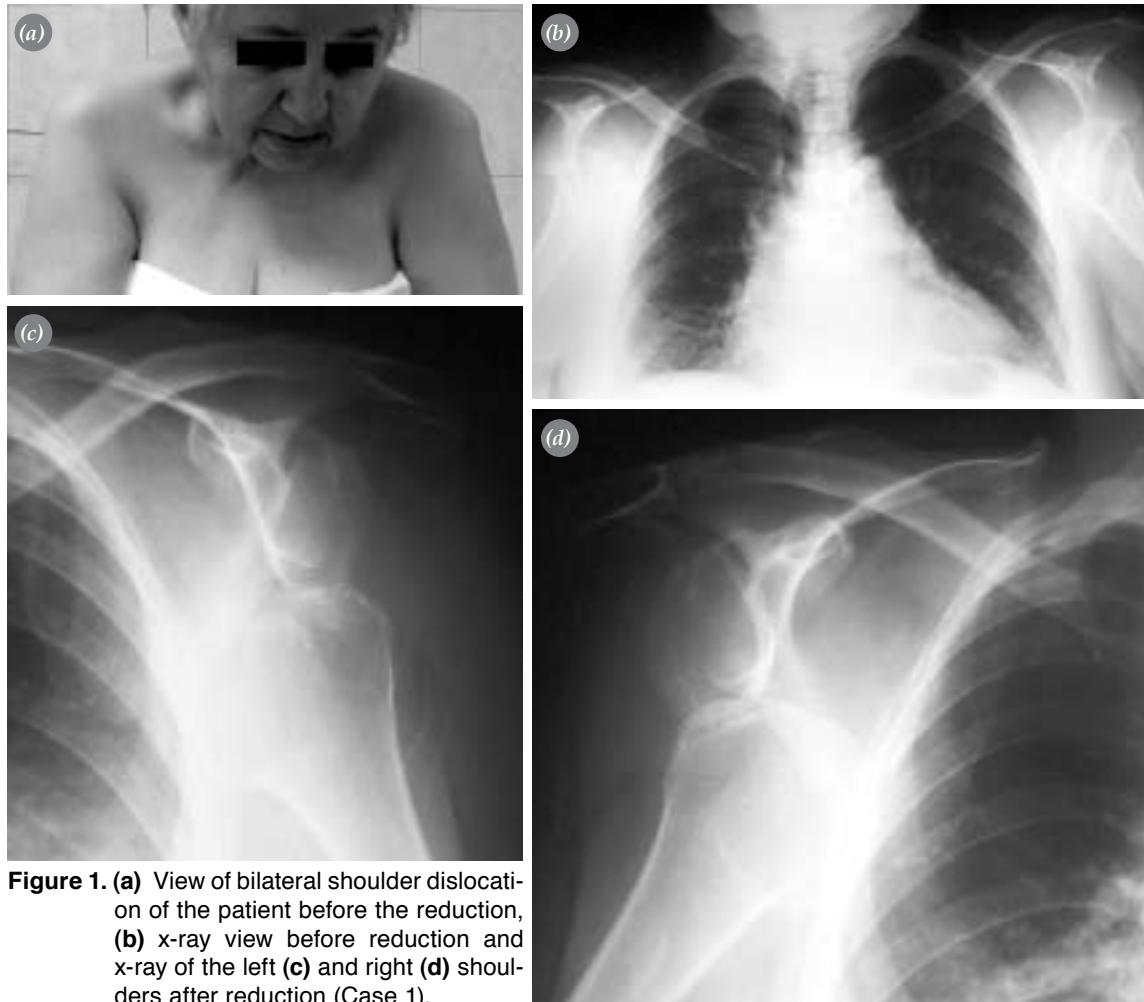


Figure 1. (a) View of bilateral shoulder dislocation of the patient before the reduction, (b) x-ray view before reduction and x-ray of the left (c) and right (d) shoulders after reduction (Case 1).

tion and external rotation (Figure 1a). Radiographic examination revealed bilateral anterior subcoracoid shoulder dislocations without any fractures (Figure 1b). After obtaining analgesia with 5 mg (iv) morphine, by the first essay, both shoulders were reduced by Kocher maneuver. Reductions were controlled by direct x-rays (Figure 1c,d). Three weeks of velpau bandage was applied after reduction in whom forward flexion and abduction were greater than 75 degrees. Pendulum exercises were begun after the end of velpau bandage. After the end of 1.5 years follow-up, there were any restricted motion or strength loss were detected and the shoulders were defined as stable.

Case 2– A 64-years-old orthopaedic casualty was presented to the emergency department with pain, deformity and restriction of movement on both sides of her shoulder. The accident was occurred in the same manner, as the first case, to protect herself from falling she grabbed a bar while she was hanging on curtains

that caused a prolonged hanged position. Physical examination of the patient revealed squared off shoulders (epaulet sign) with abduction and external rotation deformity (Figure 2a). Neurological examination showed hypoesthesia over the anterior aspect of the shoulder with loss of left sided great thumb abduction and wrist dorsiflexion. Radiological examination showed bilateral anterior subcoracoid shoulder dislocation without any fractures (Figure 2b). Under sedation, Kocher maneuver was used to reduce the shoulders in the first essay and the reduction was controlled by plain radiographs (Figure 2c,d). The strength and range of motion examination of the shoulders were normal after 3 weeks of immobilization by velpau bandage. To evaluate the neurological status, EMG was obtained and the test revealed partial axonal degeneration at the lower and posterior cords. The patient was followed-up by conservatively in whom axial pain was spreaded from shoulders to fingers and the symptoms were improved

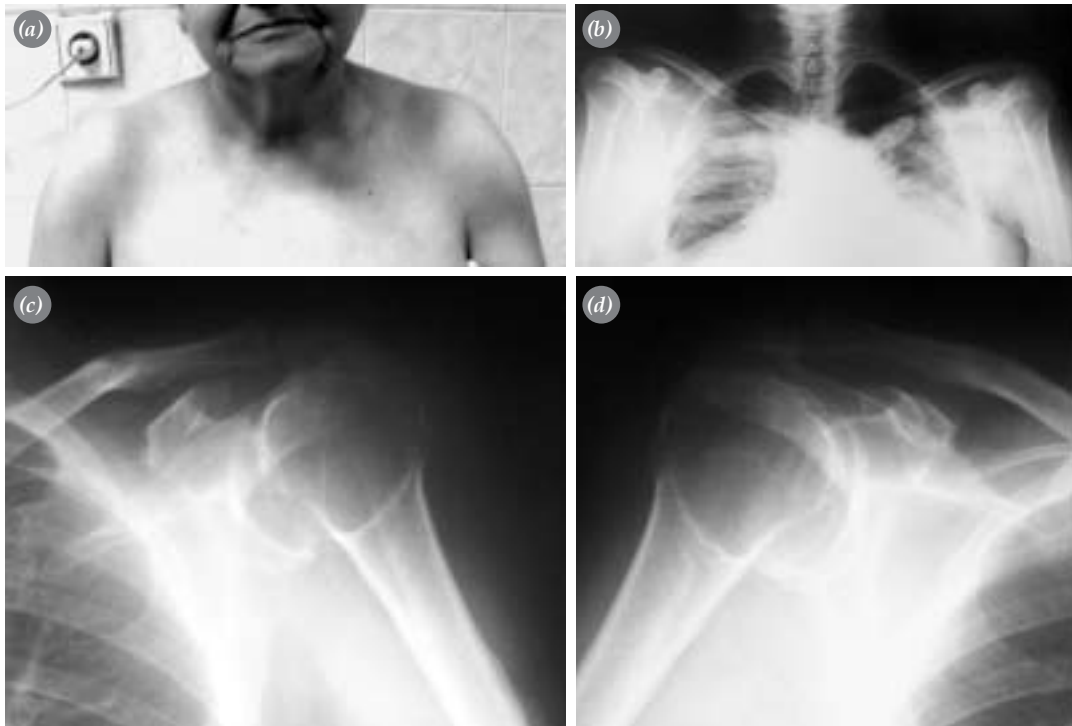

Figure 2.(a) View of the patient with bilateral shoulder dislocation before reduction, (b): x-ray obtained before reduction. X-rays of the left (c) and right (d) shoulder after reduction (Case 2).

completely at the end of sixth month. At the end of 1.5 years follow-up there were any instability or strength loss detected.

Discussion

Generally, glenohumeral dislocations are seen at the young men after a trauma. This is followed by dislocations seen at the elderly women because of increased fall risk and decrease of cross-linked collagen tissue at the joint capsule.^[5] After a trauma, coracoacromial arch and rotator cuff levers the humeral head with forced extension and abduction of the arm from the glenoid fossa in an inferior manner and flexor and external rotators levers the head to anterior manner.^[6] Of the shoulder dislocations, they were reported to be 96 % anterior, 3 % posterior and 1 % inferior.^[7] Bilateral shoulder dislocations were reported at 30 cases and bilateral anterior shoulder dislocations were reported at 8 cases.^[8]

Although posterior dislocations are seen usually after trauma, diabetic nocturnal hypoglycemia, grandmal seizures, gymnasium injuries or electric shocks, bilateral anterior dislocations are very rare and nearly all of them are on the basis of trauma.^[9-11] Delayed diagnosis could be expected for more than 10 % of ca-

ses.^[9] Complications such as fractures, brachial plexus injury, vascular and soft tissue injuries and recurring dislocations may be seen. Although preventing repeated dislocations is the primary treatment option in the younger age, complicated soft tissue injuries are the main problems in the elderly population. Rotator cuff tear risk increases and takes place of instability at the elderly.^[12] Although a controversy exists, primary management of these injuries is conservative in this population.

Electroconvulsive therapy can lead to posterior dislocations by violent muscular spasm. Brown^[13] reported the etiology of bilateral shoulder dislocations as acute spasm (41 %), trauma (23 %) and non-traumatic injuries (36 %). Emotional problems can result in asymmetric simultaneous shoulder dislocations.

The cause of dislocations in our two patients were different from the cases that were reported at the literature. As the dislocation mechanism at our cases was grab effort in an unbalanced position both created a typical shoulder dislocation mechanism. Though previously reported cases were posterior dislocations, muscular balance problems and advanced age had led to bilateral anterior dislocations in our cases. In such

cases practitioner must be alert for the probability of neurological injury.^[14]

Possible rotator cuff tears and other shoulder pathologies should be investigated by magnetic resonance imaging (MRI).^[5] MRI was not used in our cases because of advanced age and other medical problems owing to plan of conservative treatment.

In conclusion, bilateral shoulder dislocations with or without fractures are rare entities as the forces must act simultaneously in the same manner to both joints. They were reported to be seen mainly after gymnasium injuries or epileptic seizures.^[8,9] Fractures, rotator cuff ruptures or neurovascular injuries may accompany with dislocations. Especially at the older age because of balance problems and ineffective stabilizers of the shoulder, predisposition to bilateral dislocations may be higher.

References

1. Sharma L, Pankaj A, Kumar V, Malhotra R, Bhan S. Bilateral anterior dislocation of the shoulders with proximal humeral fractures: a case report. *J Orthop Surg* 2005; 13:303-6.
2. Nagi ON, Dhillon MS. Bilateral anterior fracture dislocation of the shoulders. *J Orthop Trauma* 1990;4:93-5.
3. Hintermann B, Gächter A. Theo van Rens Prize. Arthroscopic assessment of the unstable shoulder. *Knee Surg Sports Traumatol Arthrosc* 1994;2:64-9.
4. Porcellini G, Paladini P, Campi F, Paganelli M. Shoulder instability and related rotator cuff tears: arthroscopic findings and treatment in patients aged 40 to 60 years. *Arthroscopy* 2006;22:270-6.
5. Fung DA, Menkowitz M, Chern K. Asymmetric bilateral shoulder dislocation involving a luxatio erecta dislocation. *Am J Orthop* 2008;37:E97-8.
6. Solomon L, Warwick D, Nayagam S, editors. Injuries of the shoulder, upper arm and elbow. In: *Apley's system of orthopaedics and fractures*. 8th ed. London: Arnold; 2001. p. 587-91.
7. Kumar KS, O'Rourke S, Pillay JG. Hands up: a case of bilateral inferior shoulder dislocation. *Emerg Med J* 2001; 18:404-5.
8. Segal D, Yablon IG, Lynch JJ, Jones RP. Acute bilateral anterior dislocation of the shoulders. *Clin Orthop Relat Res* 1979;(140):21-2.
9. Dinopoulos HT, Giannoudis PV, Smith RM, Matthews SJ. Bilateral anterior shoulder fracture-dislocation. A case report and a review of the literature. *Int Orthop* 1999; 23:128-30.
10. Page AE, Meinhard BP, Schulz E, Toledano B. Bilateral posterior fracture-dislocation of the shoulders: management by bilateral shoulder hemiarthroplasties. *J Orthop Trauma* 1995;9:526-9.
11. Sreesobh KV, Chacko B. An unusual case of bilateral anterior dislocation of shoulder. *J Orthopaedics* 2005;2(4):e6.
12. Simank HG, Dauer G, Schneider S, Loew M. Incidence of rotator cuff tears in shoulder dislocations and results of therapy in older patients. *Arch Orthop Trauma Surg* 2006; 126:235-40.
13. Brown RJ. Bilateral dislocation of the shoulders. *Injury* 1984;15:267-73.
14. de Laat EA, Visser CP, Coene LN, Pahlplatz PV, Tavy DL. Nerve lesions in primary shoulder dislocations and humeral neck fractures. A prospective clinical and EMG study. *J Bone Joint Surg [Br]* 1994;76:381-3.