



# Excision and short segment fusion of a double ipsilateral lumbar hemivertebrae associated with a diastematomyelia and fixed pelvic obliquity

Alpaslan Senkoylu<sup>a</sup>, Mehmet Cetinkaya<sup>b,\*</sup>, Erdem Aktas<sup>c</sup>, Engin Cetin<sup>d</sup>

<sup>a</sup> Gazi University School of Medicine, Department of Orthopaedics and Traumatology, Ankara, Turkey

<sup>b</sup> Erzincan University Mengucek Gazi Training and Research Hospital, Erzincan, Turkey

<sup>c</sup> TOBB University Hospital, Department of Orthopaedics and Traumatology, Ankara, Turkey

<sup>d</sup> Gaziosmanpasa Taksim Training and Research Hospital, Department of Orthopaedics and Traumatology, Istanbul, Turkey

## ARTICLE INFO

### Article history:

Received 11 March 2018

Received in revised form

5 January 2019

Accepted 10 January 2019

Available online 2 February 2019

### Keywords:

Spine

Deformity

Congenital scoliosis

Hemivertebra

Diastematomyelia

## ABSTRACT

We report the surgical treatment course of a 4-year-old girl with congenital scoliosis, diastematomyelia and double adjacent hemivertebrae. She had a lumbar curve with an apparent pelvic obliquity. Simultaneous excision of double segmented sequential hemivertebra at the L3–L4 level and fusion with short-segment instrumentation was performed via a posterior approach. Intraoperative radiographs revealed satisfactory curve correction and 0° pelvic obliquity. Following the excision of double adjacent hemivertebrae, three adjacent nerve roots were placed in one intervertebral foramen bilaterally. Nevertheless, no neurological deficit was developed, and the patient was able to ambulate with a brace at day one. Pelvic balance and deformity correction were maintained with no implant failure at the fifth year follow-up. Excision of two ipsilateral adjacent hemivertebra and short-segment posterior fusion performed via posterior-only approach simultaneously is an effective, safe, and less invasive technique for the treatment of the described case.

© 2019 Turkish Association of Orthopaedics and Traumatology. Publishing services by Elsevier B.V. This is an open access article under the CC BY-NC-ND license (<http://creativecommons.org/licenses/by-nc-nd/4.0/>).

## Introduction

Congenital scoliosis is a deformation occurring in utero 4–6 weeks of gestation caused by a failure of formation, failure of segmentation, or both.<sup>1</sup> It is showed that mutations occurred during the development of somites or external effects to the somite formation (e.g. retinoic acid deficiency) cause vertebral anomalies including wedged vertebrae, block vertebrae, and butterfly vertebrae.<sup>2,3</sup> In 1910, Putti made a classification of congenital spine abnormalities and described the types of hemivertebra as fully-segmented, semi-segmented, and non-segmented.<sup>4</sup>

Diastematomyelia is a split spinal cord malformation developed by an anteroposteriorly trajecting bony septum or a

fibrocartilaginous tissue.<sup>5</sup> There are two different types of diastematomyelia described based on the dural sheath. In type 1, each hemicord is covered by its own dural sheath, and in type 2, two hemicords are separated by a fibrous septum and covered by same dural sheath.<sup>6</sup> Out of spinal anomalies, 4–9% are comprised by diastematomyelia, and 50–60% of these patients also have an associated scoliosis.<sup>6,7</sup> Combined diastematomyelia and hemivertebra cases are rare among the congenital scoliosis patients. There are only a few reports of outcomes or follow up results including both.<sup>8</sup> Arthrodesis in-situ, hemiepiphysiodesis, resection without instrumentation has been performed in the past with different results. In this paper, our aim was to describe the surgical technique used for the treatment of a congenital scoliosis patient with diastematomyelia combined with ipsilateral double lumbar adjacent hemivertebrae and that it was not causing any compression stress on three nerve roots coursing through one intervertebral foramen.

\* Corresponding author. Erzincan Binali Yildirim University Mengucek Gazi Training and Research Hospital, Department of Orthopaedics and Traumatology, Merkez, Erzincan, 24100, Turkey. Tel.: +90 532 7969887. Fax: +90 312 2129008.

E-mail address: [drcetink@gmail.com](mailto:drcetink@gmail.com) (M. Cetinkaya).

Peer review under responsibility of Turkish Association of Orthopaedics and Traumatology.

## Case report

### Patient characteristics

A 4-year-old girl presented to our institution with a curvature on her back (Fig. 1). Radiographs revealed sequential double L3–L4 hemivertebrae with a 56° right-sided lower (L2–L5) and 34° left-sided upper lumbar (T9–L1) curves according to Cobb's method (Fig. 2). The unbalanced double lumbar curves were compensated by high left hip pelvic obliquity. The preoperative radiographs revealed an apparent pelvic obliquity towards the right side in order to level her shoulders. The pelvic obliquity angle was measured 34° (Fig. 2). The lateral bending radiographs taken with the patient upright and unsupported revealed that the obliquity of the pelvis was fixed because of the lumbar curvature. She was previously diagnosed with diastematomyelia and underwent surgical excision a year ago (Fig. 3). The surgical intervention had been performed successfully, and the postoperative period was uneventful. The neurological examination revealed full strength and normal sensation in her lower extremities. Bowel and bladder functions were noted to be normal. Based on the above data, the potential risk for spinal deformity and pelvic obliquity progression was considered to be high in this patient, thus resection of both hemivertebra combined with correction of the deformity in a single stage procedure was planned for this patient.

### Surgical technique

Under multimodal intraoperative neuromonitoring with motor-evoked potentials (MEP), somatosensory-evoked potentials (SEP), and triggered electromyography (EMG), posterior-only approach was performed by standard single midline incision to expose the L3 and L4 hemivertebrae. Extended exposure was avoided to prevent spontaneous fusion above the L2 vertebra. Pedicle screws were placed to L2 and L5 levels bilaterally. Transverse processes of L3–L4 hemivertebrae were excised initially at convex side. This facilitated finding pedicles and vertebral body of these hemivertebrae by blunt dissection. Laminae were resected with No. 1 Kerrison Rongeur. A surgical cotton patty was used for blunt dissection of dura

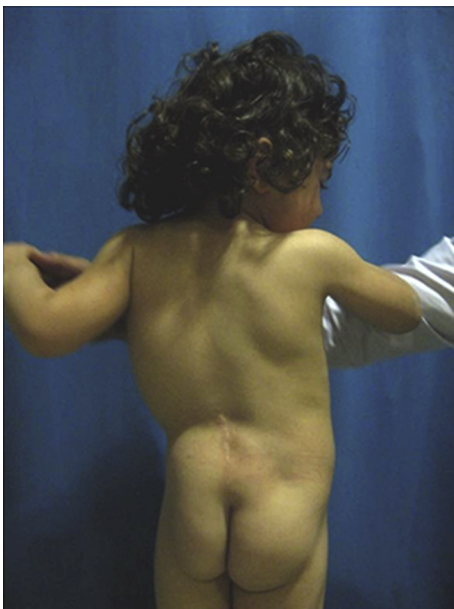

Fig. 1. Clinical appearance of the deformity at the time of presentation.

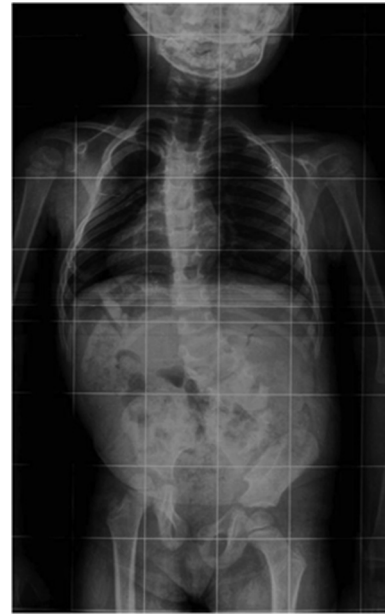


Fig. 2. Preoperative X-ray revealing sequential double L3–L4 hemivertebra with a 56° right-sided lower and 34° left-sided upper lumbar curve, and an apparent pelvic obliquity towards the right side in order to level her shoulders with a 34° pelvic obliquity angle.

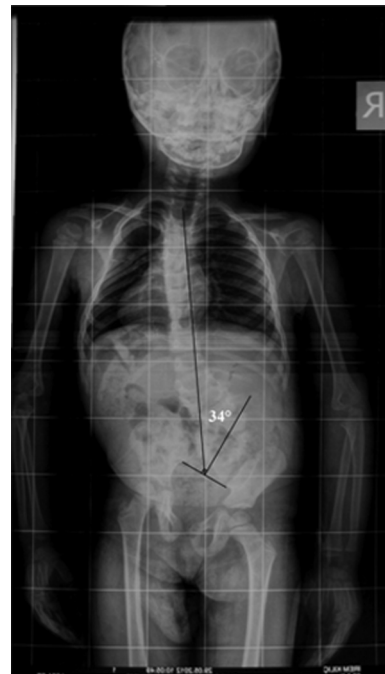

Fig. 3. MRI images showing diastematomyelia prior surgical excision of the lesion.

during resection in order to prevent incidental dural tear caused by adhesions resulted from previous surgery. The nerve roots were skeletonized and protected. A Hohmann retractor was placed anterolaterally to the L3 hemivertebra to protect neurovascular structures at risk, and L3 corpectomy was performed. The same step was performed for L4. The SEP, MEP, and triggered EMG revealed no abnormality during the procedure. Following the resection of L3 and L4 hemivertebrae, two vertical rods were attached to the previously placed pedicle screws. Compression at

the convex side and distraction at the concave side of the curve were performed to correct the lumbar deformity and pelvic obliquity. There was no intraoperative neuromonitoring signal decrement recorded during this critical manoeuvre. Consequently, all L2, L3, and L4 nerve roots were together in one intervertebral foramen and were exiting through the space between L2 and L5 vertebral bodies (Fig. 4). Radiographs taken intraoperatively were satisfactory with 0° scoliosis and 0° pelvic obliquity (Fig. 5). Postoperative early neurological findings were recorded to be normal, and the complaints of the patient were only vomiting and nausea until the postoperative day two. The patient was mobilized with a rigid Boston-brace starting from postoperative day one and was recommended to use the brace for three months. The patient was discharged at day seven with no wound problem and neurologic deficit, and follow-ups were scheduled at 1st month, 3rd month, 6th month, 1st year, 2nd year, 5th year, and 10th (possibly after the end of growth spurt with puberty) year. At the end of the fifth year follow-up, postoperative clinic and radiographs revealed favourable results with no scoliosis and pelvic obliquity (Fig. 6a–c).

## Discussion

Prior to surgical intervention of a hemivertebra formation at the lumbar region in a scoliosis patient, MRI is mandatory as this deformity can be accompanied by a cord malformation. Our patient had a type 1 split cord malformation in which each hemicord was covered by its own dural sheath, and the patient underwent excision of the bony septum before scoliosis surgery. Because, if the hemivertebra formation and diastematomyelia exist in a patient together, it can be devastating to stretch and move the spinal cord with a bony septum passing through it during the correction.

The incidence of hemivertebra formation was reported to be 0.09 per 1000 births, and the rate of a second congenital spine anomaly was reported to be 10%.<sup>9</sup> If it is considered that only some

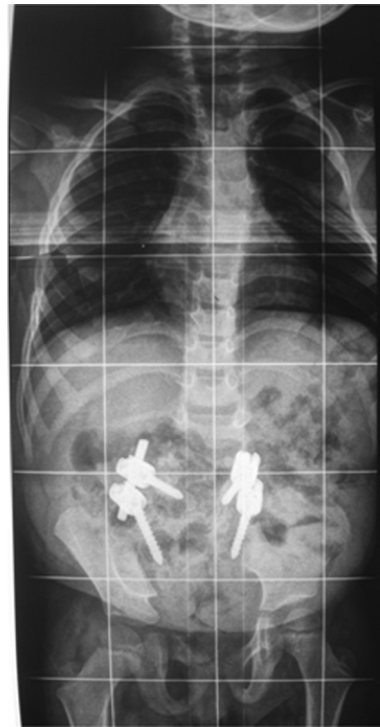

Fig. 5. Intraoperative X-ray was satisfactory with 0° scoliosis and 0° pelvic obliquity.

of second congenital anomalies are diastematomyelia and only some of these patients develop scoliosis, one can easily say that the combination of the hemivertebra formation with diastematomyelia is quite rare. In the case described by the current study, the hemivertebra formation was in the lumbar region and there were two of

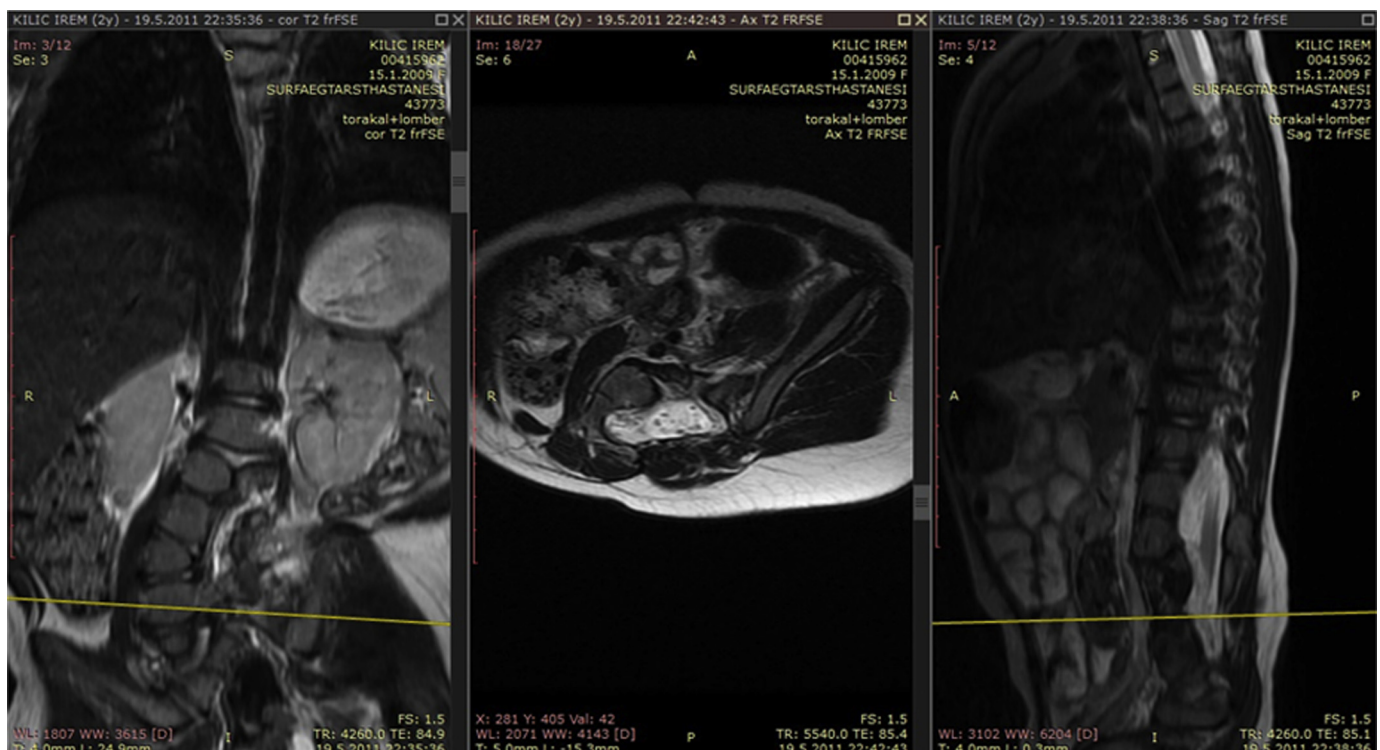
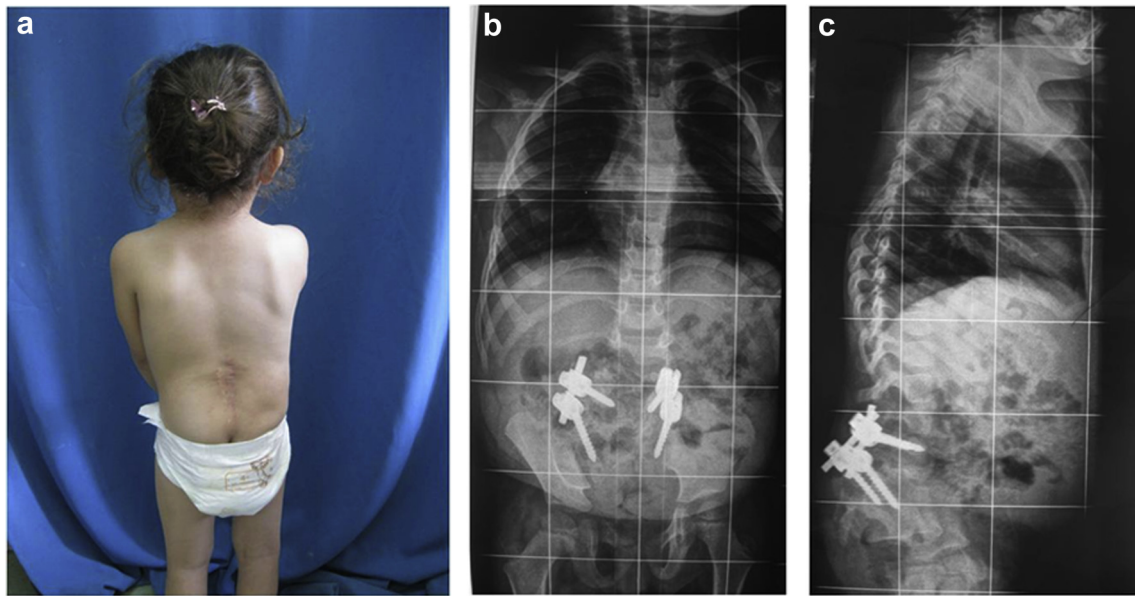


Fig. 4. Schematic of L2, L3, and L4 nerve roots together in one intervertebral foramen, exiting through the space between L2 and L5 vertebral bodies following L3, L4 resection.





**Fig. 6.** Clinical appearance (a), anteroposterior X-ray (b) and lateral X-ray (c) of the patient in postoperative fifth year.

them which were adjacent to each other and ipsilateral. It seems that all these features were the reason why this case is very rare and has not published in the literature before.

It has to be kept in mind that hemivertebrae are usually encountered in thoracic regions, although lumbar hemivertebra is noted to be as high as 8% of the cases.<sup>10</sup> In our patient, both hemivertebrae were fully-segmented, ipsilateral and adjacent to each other. Contralateral placement of a second hemivertebra may compensate deforming effects of a single hemivertebra while multiple ipsilateral hemivertebrae facilitate deforming effects as in this case. In this study, both of hemivertebrae were causing severe pelvic obliquity, and trunk shift had developed over time. The trunk shift and pelvic obliquity are usually less severe with hemivertebrae located in upper thoracic segments. It is recommended to excise hemivertebrae with an early intervention, otherwise, compensatory cranial or caudal structural curves may develop in neglected cases.<sup>11,12</sup>

Arthrodesis in-situ, hemiepiphysiodesis, and resection without instrumentation had been performed in the past with different results. Hemivertebra resection with spinal instrumentation through anterior and posterior approach has been advocated as the treatment of choice. The papers reporting the comparable results of posterior hemivertebra resection (HVR) show that it has become the preferred surgical procedure recently.<sup>13</sup> HVR can be accomplished by combined anterior-posterior procedures in single-stage, two-stage or simultaneously. Although recent studies suggest that unilateral posterior approach with a single rod and pedicle screw instrumentation is promising, there are concerns about the surgical approach. Compared to combined anteroposterior approach (CAPA), implant failure is known to be more frequent with posterior-only approach.<sup>14</sup> Some studies advise placing a third rod or postoperative bracing to enhance the stability.<sup>15,16</sup> Because of an existing scar tissue of the previous surgery and the advantage of limited soft tissue exposure after, the posterior only approach with a short segment fusion, as the more frequently preferred surgical option with similar results,<sup>13</sup> was preferred for this 4-year-old female patient, and no implant failure occurred during the 5-year follow-up.

Spinal canal narrowing in these cases is an important issue. Because of the pedicle screws attached each other via rods, lateral

expansion of the inter-pedicular diameter of the vertebrae is impossible. Ruf et al reported nearly normal growth of the instrumented pedicles in terms of anterior-posterior and upper-lower lengths in comparison with adjacent vertebrae,<sup>17</sup> but lateral lengths. However, we know that the diameter of the spinal canal is fully mature within the first years of life.<sup>18</sup> Regarding these data, we considered posterior instrumentation as a safe and effective method in our 4-year-old patient.

After the excision of hemivertebra, the risk of neurologic injury is well-documented and may involve either a nerve root or spinal cord lesion, especially with CAPA.<sup>19</sup> Fortunately, most of these studies did not report irreversible neurologic deficits after this approach.<sup>20</sup>

With posterior-only approach, the rates of correction in the main and the compensatory curves were comparable to CAPA.<sup>16</sup> On the other hand, posterior-only approach facilitates less intraoperative blood loss compared to CAPA.<sup>19</sup> Malden and colleagues showed no significant difference between CAPA and posterior-only procedures. This might be due to the early performed SRS-24 questionnaire revealing better subjective satisfaction with posterior-only approach.<sup>7,16</sup> In the light of the above information, we preferred to perform hemivertebra resection by the posterior-only approach in our patient for ipsilateral adjacent double hemivertebra excision. Even after the resection of sequential two hemivertebrae (L3, L4), all three nerve roots L2, L3, L4 accommodated in the same intervertebral foramen very well with no postoperative neurological deficit. Another problem was the big gap to be closed between the L2 and L5 after excising the hemivertebrae L3 and L4. Although it is challenging to close the space developed between the upper and lower vertebrae after the resection of adjacent two hemivertebrae, we concluded that approximating the L2 and L5 vertebrae by compression of the pedicle screws on rods is effective and safe. In the presented case, we did not detect any signal decrement during this manoeuvre by intraoperative neuromonitoring. During the correction manoeuvre, we suggest surgeons to meticulously follow the intraoperative neurologic alterations by using continuous neuromonitoring, especially with triggered EMG.

In conclusion, according to the literature review and the current study, it can be stated that the posterior-only approach for deformity correction and short-segment fusion is a safe, effective, and

applicable method for the lumbar hemivertebra formations. This case also revealed that three nerve roots can be accommodated very well in a single intervertebral foramen without any neurologic disruption.

## References

1. Liu YT, Guo LL, Tian Z, et al. A retrospective study of congenital scoliosis and associated cardiac and intraspinal abnormalities in a Chinese population. *Eur Spine J*. 2011;20(12):2111–2114.
2. Vermot J, Pourquie O. Retinoic acid coordinates somitogenesis and left-right patterning in vertebrate embryos. *Nature*. 2005;435(7039):215–220.
3. Vilhais-Neto GC, Maruhashi M, Smith KT, et al. Rere controls retinoic acid signalling and somite bilateral symmetry. *Nature*. 2010;463(7283):953–957.
4. Putti V. Die angeborenen deformitäten der Wirbelsäule. *Fortschr Roentgenstr*. 1910;15:65–76.
5. Gavrilu S, Vlad C, Georgescu I, Burnei G. Diastematomyelia in congenital scoliosis: a report of two cases. *Eur Spine J*. 2014;23(Suppl 2):262–266.
6. Hood RW, Riseborough EJ, Nehme AM, Micheli LJ, Strand RD, Neuhauser EB. Diastematomyelia and structural spinal deformities. *J Bone Joint Surg Am*. 1980;62(4):520–528.
7. Mladenov K, Kunkel P, Stuecker R. Hemivertebra resection in children, results after single posterior approach and after combined anterior and posterior approach: a comparative study. *Eur Spine J*. 2012;21(3):506–513.
8. Leung YL, Buxton N. Combined diastematomyelia and hemivertebra: a review of the management at a single centre. *J Bone Joint Surg Br*. 2005;87(10):1380–1384.
9. Passias PG, Poorman GW, Jalai CM, et al. Incidence of congenital spinal abnormalities among pediatric patients and their association with scoliosis and systemic anomalies. *J Pediatr Orthop*. 2017.
10. Mohanty S, Kumar N. Patterns of presentation of congenital scoliosis. *J Orthop Surg (Hong Kong)*. 2000;8(2):33–37.
11. Nasca RJ, Stilling FH, Stell 3rd HH. Progression of congenital scoliosis due to hemivertebrae and hemivertebrae with bars. *J Bone Joint Surg Am*. 1975;57(4):456–466.
12. McMaster MJ. Spinal growth and congenital deformity of the spine. *Spine (Phila Pa 1976)*. 2006;31(20):2284–2287.
13. Huang Y, Feng G, Song Y, et al. Efficacy and safety of one-stage posterior hemivertebra resection for unbalanced multiple hemivertebrae: a more than 2-year follow-up. *Clin Neurol Neurosurg*. 2017;160:130–136.
14. Wang S, Zhang J, Qiu G, Li S, Yu B, Weng X. Posterior hemivertebra resection with bisegmental fusion for congenital scoliosis: more than 3 year outcomes and analysis of unanticipated surgeries. *Eur Spine J*. 2013;22(2):387–393.
15. Hedequist D, Emans J, Proctor M. Three rod technique facilitates hemivertebra wedge excision in young children through a posterior only approach. *Spine (Phila Pa 1976)*. 2009;34(6):E225–E229.
16. Jalanko T, Rintala R, Puisto V, Helenius I. Hemivertebra resection for congenital scoliosis in young children: comparison of clinical, radiographic, and health-related quality of life outcomes between the anteroposterior and posterolateral approaches. *Spine (Phila Pa 1976)*. 2011;36(1):41–49.
17. Ruf M, Harms J. Hemivertebra resection by a posterior approach: innovative operative technique and first results. *Spine (Phila Pa 1976)*. 2002;27(10):1116–1123.
18. Ferree BA. Morphometric characteristics of pedicles of the immature spine. *Spine (Phila Pa 1976)*. 1992;17(8):887–891.
19. Holte DC, Winter RB, Lonstein JE, Denis F. Excision of hemivertebrae and wedge resection in the treatment of congenital scoliosis. *J Bone Joint Surg Am*. 1995;77(2):159–171.
20. Leatherman KD, Dickson RA. Two-stage corrective surgery for congenital deformities of the spine. *J Bone Joint Surg Br*. 1979;61-B(3):324–328.