



# A case of isolated tuberculous tenosynovitis of the flexor tendon of the third finger of the hand

## *El üçüncü parmak fleksör tendonunda izole tüberküloz tenosinoviti: Olgu sunumu*

I. Bulent OZCELİK,<sup>1</sup> Tefrik SULUN,<sup>2</sup> Emre ORHUN<sup>3</sup>

<sup>1</sup>Ist-El Hand Surgery, Microsurgery, and Rehabilitation Group

(TEM Hospital Hand Surgery Department - Gaziosmanpaşa Hospital Hand Surgery Department);

<sup>2</sup>Gemeinschaftspraxis für Orthopädie; <sup>3</sup>Istanbul Hospital Ortopedi ve Traumatoloji department

Elli beş yaşında kadın hasta, sağ el ayasında ağrısız şişlik ve üçüncü parmakta hareket kısıtlılığı yakınmasıyla başvurdu. Manyetik rezonans görüntüleme, sağ el üçüncü parmak fleksör tendon kılıfında, heterojen kontrast tutan sinovyal lezyon görüldü. Açık biyopsi sonrası yapılan patolojik incelemede kazeifiye granülomatöz iltihabi reaksiyon saptandı. Biyopsi sonrası tüberküloz tanısı konarak antitüberküloz kemoterapiye başlandı. Dokuz ay sürdürülen antitüberküloz tedaviyle, geniş cerrahi girişime gerek kalmadan tam iyileşme sağlandı. Hastanın dokuzuncu ayda yapılan kontrolünde eklem hareketleri ağrısız ve açıktı.

**Anahtar sözcükler:** Parmak eklemi; tenosinovit/tanı/tedavi; tüberküloz, osteoartiküler/tanı/tedavi.

A 55-year-old female patient presented with a painless swelling in the palm of the right hand, causing restriction of the third finger. Magnetic resonance imaging revealed a synovial lesion in the flexor tendon sheath of the third finger, showing heterogenous contrast. Open biopsy and histopathological studies showed a granulomatous infectious reaction of the synovial tissue. A diagnosis of tuberculosis was made, after which antituberculosis treatment was instituted. Total regression was achieved after nine months of medical treatment without further extensive surgical measures. At the end of nine months, the movements of the finger were found to be normal and painless.

**Key words:** Finger joint; tenosynovitis/diagnosis/therapy; tuberculosis, osteoarticular/diagnosis/therapy.

Majority of the non-pulmonary tuberculosis are seen in musculoskeletal system. It is a chronic and progressive disease that mostly affects weight bearing joints.<sup>[1, 2]</sup> Upper extremity presentations are not common<sup>[2, 3]</sup> and diagnosis may be late with an unusual clinical picture.<sup>[1]</sup> A case with isolated flexor tendon tuberculosis tenosynovitis of the third finger is presented.

### Case report

A 55 year old female patient presented with a slowly growing painless mass in third finger of the right hand. The swelling started two years ago in the

third finger but expanded to midpalmar area by time. There has been a continuous discharge from the fistula in the dorsal aspect of the finger. There was no history of tuberculosis in the patient and her family. Clinical examination revealed a painless swelling in palmar and dorsal aspect of third finger and in the course of flexor tendon sheath through midpalmar area. There was a serous discharge from the fistula in the dorsolateral aspect of third finger. There was no pain, sensory loss or vascular compromise but the joint movements were restricted due to swelling. There was no sign of pulmonary tuberculosis in clinical examinations and chest x-rays. The x-rays of the

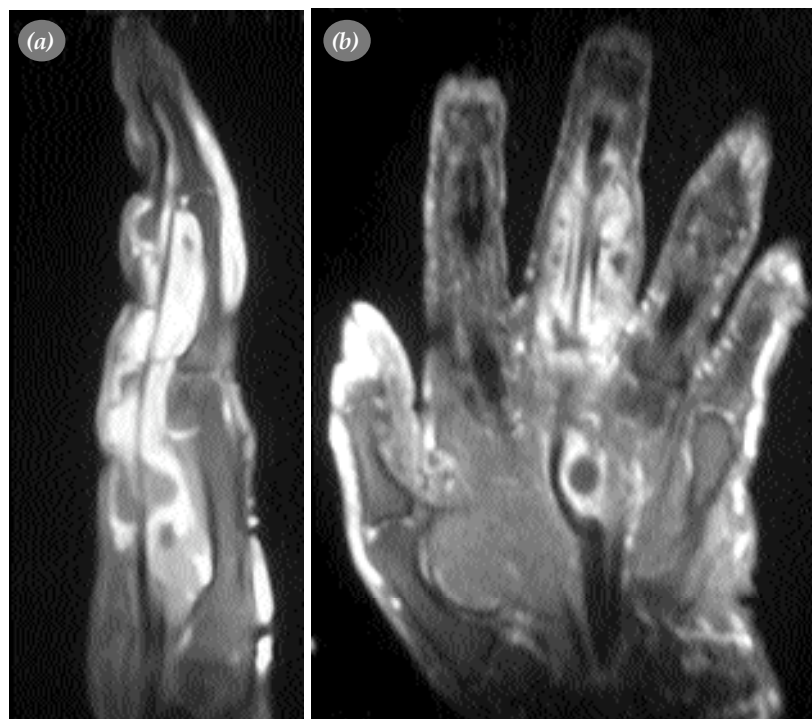
hand showed nothing more than soft tissue edema. MRI revealed a synovial lesion surrounding flexor tendons of third finger from distal aspect of flexor retinaculum to middle phalanx. The heterogeneous lesion was enhanced with contrast injection and composed of solid and cystic areas (Figure 1). All laboratory tests were normal with a sedimentation rate of 28 mm/hour. The purified protein derivative (PPD) test was positive.

Open biopsy was performed and thickened synovium with many particles like rice was observed. Both the synovium and the particles were biopsied. The results of biopsy showed granulomatous lesions containing multinuclear giant cells with some central necrosis. There were epithelioid fibroblasts and mononuclear inflammatory cells. Histologically the lesion was a tuberculosis lesion. However no asit-resistant bacillus, bacteria or fungus was observed. Aerobic and anaerobic culture results were negative.

Tuberculous tenosynovitis was diagnosed histologically and antituberculous treatment was started (isoniazid, rifampin, pyrazinamide, ethambutol). Pyrazinamide and ethambutol was stopped after third month. Antituberculous treatment was continued for nine months with isoniazid and rifampin. The lesion was regressed and the discharge was stopped after six weeks of therapy. Nine months of antituberculous therapy completely treated the patient without any surgical intervention.

### Discussion

Non-pulmonary tuberculosis results from hematogenous spread of disease from active or inactive infected organs such as lungs, lymphatics, or other visceral organs.<sup>[3, 5]</sup> Painless progressive swelling through tendons even without any other systemic sign or evidence must remind tuberculosis.<sup>[3, 6]</sup> Enhancement with contrast injection in MRI is helpful in diagnosis of chronic tenosynovitis and



**Figure 1.** (a) Axial MRI images demonstrating marked thickening of flexor tendon synovial sheath of third finger. (b) Coronal MRI with contrast injection revealed a synovial lesion surrounding flexor tendons of third finger from distal aspect of flexor retinaculum to middle phalanx. The heterogeneous lesion was enhanced with contrast injection and composed of solid and cystic areas.

tuberculosis. Contrast injection will reveal the extent of mass and synovial thickening.<sup>[7]</sup>

Specimens should be taken both for histological and microbiological studies. The diagnosis of tuberculosis is possible with positive histological or culture results.<sup>[3, 8]</sup> The decision to start antituberculosis therapy in our case was made with positive histological studies. Culture techniques are complex and results may take six to eight weeks also there may be false negative results.<sup>[2, 3]</sup>

Surgical debridement is controversial.<sup>[3, 5]</sup> There are studies proposing surgical debridement.<sup>[3, 9]</sup> Tuli states that surgical debridement should be performed in patients who do not respond to four or five months of chemotherapy.<sup>[5]</sup> We planned the surgical debridement in this case after the chemotherapy, because chemotherapy before the surgery prevents dissemination of the disease as milliary and meningeal tuberculosis.<sup>[5]</sup> However there has been complete remission of the disease with chemotherapy in our case so no surgery was performed.

Surgery may cause adhesions especially in palmar side of hand so antituberculosis therapy should be tried first. Patients should be given an exercise

program during antituberculosis therapy to improve functional results.

In conclusion non-pulmonary tuberculosis can present in atypical locations.

## References

1. Hunfeld KP, Rittmeister M, Wichelhaus TA, Brade V, Enzensberger R. Two cases of chronic arthritis of the forearm due to Mycobacterium tuberculosis. *Eur J Clin Microbiol Infect Dis* 1998;17:344-8.
2. Skoll PJ, Hudson DA. Tuberculosis of the upper extremity. *Ann Plast Surg* 1999;43:374-8.
3. Bush DC, Schneider LH. Tuberculosis of the hand and wrist. *J Hand Surg [Am]* 1984;9:391-8.
4. Robins RH. Tuberculosis of the wrist and hand. *Br J Surg* 1967;54:211-8.
5. Tuli SM. General principles of osteoarticular tuberculosis. *Clin Orthop Relat Res* 2002;(398):11-9.
6. Esenyel CZ, Bulbul M, Kara AN. Isolated tuberculous tenosynovitis of the flexor tendon of the fourth finger of the hand. Case report. *Scand J Plast Reconstr Surg Hand Surg* 2000;34:283-5.
7. Sueyoshi E, Uetani M, Hayashi K, Kohzaki S. Tuberculous tenosynovitis of the wrist: MRI findings in three patients. *Skeletal Radiol* 1996;25:569-72.
8. Visuthikosol V, Kruavit A, Nitiyanant P, Siriwongpairat P. Tuberculous infection of the hand and wrist. *Ann Plast Surg* 1996;37:55-9.
9. Cramer K, Seiler JG 3rd, Milek MA. Tuberculous tenosynovitis of the wrist. Two case reports. *Clin Orthop Relat Res* 1991;(262):137-40.