



# The results of arthroscopic repair of full-thickness tears of the rotator cuff

## *Rotator manşetin tam kat yırtıklarında artroskopik tamir sonuçları*

Mehmet Ugur OZBAYDAR, Murat TONBUL, Okan YALAMAN

*Okmeydani Teaching Hospital, Orthopaedic Surgery Department, Istanbul*

**Amaç:** Rotator manşette tam kat yırtık tanısıyla artroskopik tamir uygulanan hastalarda fonksiyonel sonuçlar değerlendirildi ve manyetik rezonans görüntüleme (MRG) ile rotator manşette yağlı dejenerasyon miktarı ve yeniden yırtık oluşumu araştırıldı.

**Çalışma planı:** Konservatif tedaviye yanıt vermeyen 22 hastada (9 erkek, 13 kadın; ort. yaş 56; dağılım 38-71) tam kat rotator manşet yırtığı nedeniyle artroskopik rotator manşet tamiri yapıldı. Ameliyat öncesi ortalama izlem süresi 15 ay (45 gün-120 ay) idi. On yedi hastada sağ, beş hastada sol omuz tutulmuştu; bunların %77'si dominant taraftaydı. Hareket açıklıkları gonyometre ile, kas kuvvetleri manuel olarak ölçüldü. Klinik ve fonksiyonel sonuçlar fizik muayene, Amerikan Omuz ve Dirsek Cerrahları (ASES) skorlaması ve UCLA skalası ile değerlendirildi; rotator manşetteki dejenerasyon ve tekrarlayan yırtık oluşumu MRG ile araştırıldı. Ameliyattan sonra ortalama izlem süresi 24 ay (12-36) idi.

**Sonuçlar:** Ameliyat öncesi aktif öne fleksiyon açıklığı ortalama 105°, aktif dış rotasyon 41° iken, ameliyat sonrasında sırasıyla 160° ( $p<0.05$ ) ve 44° ( $p>0.05$ ) ölçüldü. Supraspinatus ve infraspinatus kas kuvvetleri ameliyattan sonra anlamlı derecede arttı ( $p<0.05$ ). Ortalama ASES skoru (25.4 ve 86.7) ve UCLA skalası puanı (10.6 ve 25.6) ameliyat sonrasında anlamlı artış gösterdi ( $p<0.05$ ). Ortalama iyileşme süresi üç ay (dağılım 1-12 ay) idi. Yirmi hasta (%90.9) ameliyat sonucundan memnun kaldığını bildirdi. Manyetik rezonans görüntülemeye yedi hastada (%31.8) yırtığın tekrarladığı görüldü. Rotator manşette ameliyat öncesi ve sonrası hesaplanan dejenerasyon oranları anlamlı farklılık göstermedi ( $p>0.05$ ).

**Çıkarımlar:** Tam kat rotator manşet yırtıklarının artroskopik tamirinde klinik ve fonksiyonel başarı oranları yüksektir.

**Anahtar sözcükler:** Artroskopi/yöntem; manyetik rezonans görüntüleme; hasta memnuniyeti; hareket açıklığı, eklem; rotator manşet/yaralanma/cerrahi; yırtık; tedavi sonucu.

**Objectives:** This study was designed to evaluate the functional results of arthroscopic repair of full-thickness tears of the rotator cuff and to investigate the degree of fatty degeneration of the rotator cuff muscles and recurrent ruptures by magnetic resonance imaging (MRI).

**Methods:** Twenty-two patients (9 males, 13 females; mean age 56 years; range 38 to 71 years) underwent arthroscopic repair of full-thickness tears of the rotator cuff following conservative treatment for a mean of 15 months (range 45 days to 120 months). Involvement was in the right shoulder in 17 patients, being on the dominant side in 77%. The range of motion was measured with a goniometer, and muscle strength by manual examination. Clinical and functional evaluations were made by physical examination and according to the American Shoulder and Elbow Surgeons Standardized Shoulder Assessment Form (ASES) and the UCLA scale. Fatty degeneration of the rotator cuff muscles and recurrence were analyzed by MRI. The mean follow-up was 24 months (range 12 to 36 months).

**Results:** The mean active forward flexion and external rotation increased from 105° to 160° ( $p<0.05$ ) and from 41° to 44° ( $p>0.05$ ), respectively. The strength of the supraspinatus and infraspinatus muscles significantly increased ( $p<0.05$ ). The mean ASES and UCLA scores significantly increased from 25.4 to 86.7 and from 10.6 to 25.6, respectively ( $p<0.05$ ). The mean healing time was three months (range 1 to 12 months). Twenty patients (90.9%) were satisfied with the result of the treatment. On MRI scans, recurrent ruptures were detected in seven patients (31.8%); the extent of fatty degeneration of the rotator cuff muscles did not differ pre- and postoperatively ( $p>0.05$ ).

**Conclusion:** Arthroscopic repair of full-thickness tears of the rotator cuff yields high clinical and functional success rates.

**Key words:** Arthroscopy/methods; magnetic resonance imaging; patient satisfaction; range of motion, articular; rotator cuff/injuries/surgery; rupture; treatment outcome.

Rotator cuff repair is one of the most frequent procedures performed in the shoulder joint. Neer<sup>(1)</sup> in 1972, reported the results of his patients who underwent a rotator cuff mobilization and repair procedure accompanied with anterior acromioplasty and defined the surgical principals of rotator cuff repair. It is proved that by applying these principals, successful results can be obtained.<sup>(2)</sup> Recently, by developments in surgical equipments and repair techniques, great improvement in rotator cuff surgery is obtained. Surgical technique develops through traditional open repair to arthroscopic assisted mini-open technique and furthermore to a less invasive method; full arthroscopic repair. It is under debate, whether which technique is over to one another. However, full arthroscopic rotator cuff repair still develops to become a choice for traditional open and arthroscopic assisted mini-open repair.<sup>(3)</sup>

Arthroscopic rotator cuff repair has several advantages. With this technique it is possible to use a much little incision and to protect the deltoid muscle. It provides to diagnose and to treat the intra-articular lesions; rotator cuff may be released and mobilized with this technique; soft tissue damage is minimized, thus, postoperative pain decreases, rehabilitation is facilitated and the risk of adhesive capsulitis is decreased. However, sufficient stabilization of the tendon to the bone with suture anchors is still controversial.<sup>(2)</sup>

This study was designed to evaluate the functional results of arthroscopic repair of full-thickness tears of the rotator cuff and to investigate the degree of fatty degeneration of the rotator cuff muscles and recurrent ruptures by magnetic resonance imaging (MRI).

## Patients and methods

34 patients underwent arthroscopic rotator cuff repair for full thickness rotator cuff tears unresponsive to conservative treatment between 2000 and 2003. This study included twenty-two patients (9 male, 13 females; mean age 56 years; range 38 to 71 years) who came to their last follow-up, and of whom pre and postoperative MRI could be reached.

The mean follow-up was 24 months (range 12 to 36 months). Involvement was in the right shoulder in 17 patients, being on the dominant side in 77%.

Tears occurred after severe trauma in twelve patients. The main complaint was pain in 11 patients; pain and weakness in 10 and only weakness in one patient.

Clinical and functional evaluations were made by physical examination and according to the American Shoulder and Elbow Surgeons Standardized Shoulder Assessment Form (ASES) and the UCLA scale. Fatty degeneration of the rotator cuff muscles and recurrence were analyzed by MRI (4,5).

At the latest follow-up the range of motion was measured with a goniometer, and muscle strength by manual examination.

ASES scores (max. 100 points), were calculated pre and postoperatively consisting daily living activities and visual analog scores. UCLA scale (max 35 points), were calculated pre and postoperatively consisting pain (10 points), function (10 points), active forward flexion (5 points), manual forward flexion strength (5 points) and patient satisfaction (5 points). 34-35 points are esteemed to be excellent, 28-33 points good, 21-27 points fair and 0-20 points poor.

Pre and postoperative MRIs are interpreted by the same radiologist who didn't know the clinical results. The constancy of the tendons and recurrent ruptures are appraised according to T<sub>2</sub>-weighted coronal oblique and proton density images and also to short inversion recovery sequences. Thus, defect of constancy in a tendon or fluid like image in at least one image in T<sub>2</sub>-weighted or fat suppressed sequences is interpreted as full thickness rotator cuff tear.<sup>(6)</sup>

For qualitative and quantitative interpretation of the rotator cuff muscles, parallel, sagittal and oblique in relation to the glenohumeral joint and T<sub>1</sub>-weighted images are obtained. In the scapular Y image, the supraspinatus pit and the infraspinatus muscles are measured quantitatively<sup>(7)</sup>. The rate of the whole muscle mass to the intramuscular fatty degeneration and the amount of atrophy is calculated according to the computerized tomography method described by Goutallier et al.<sup>(8)</sup> and to the MRI method described by Fuchs et al.<sup>(9)</sup> Goutallier named stage 0, for any fatty infiltration; stage 1 for minimal fatty infiltration; stage 2 for fat amount less

than the muscle; stage 3 for equal amounts of fat and muscle, and stage 4 for fat amount more than the muscle. We calculated the rate of the fatty degeneration to the whole muscle mass on scapula Y planes on MRI by using standard millimetric papers (Figure 1a, b).

The size of the rupture is measured from the gap after a one to two millimeters of a debridement. Ruptures less than one cm is esteemed to be small; 1 to 3 cm mid; 3 to 5 cm large and more than 5 cm massive. Statistical analysis was made using the t-test.

### Operative technique

Patients were operated under general anesthesia and in beach-chair position. Posterior, anterior and lateral portals were used and intraarticular pathologies were diagnosed. First, the subacromial decompression was performed. Lateral side of the humeral articular cartilage is debrided until appropriate hemorrhagic surface is obtained. About one to three, 5.0 mm suture anchors have been used for rotator cuff repair.

Postoperatively, abduction arm slings and cryocuffs are applied to the patients. Pendular, passive elevation and external rotation exercises are begun after the first operative day. The patients were discharged at the second day. They wore off the slings at the fourth week and started tensile exercises in order to improve the joint movement. These exercises lasted for at least one year postoperatively. The mean follow-up was 24 months (range 12 to 36 months).

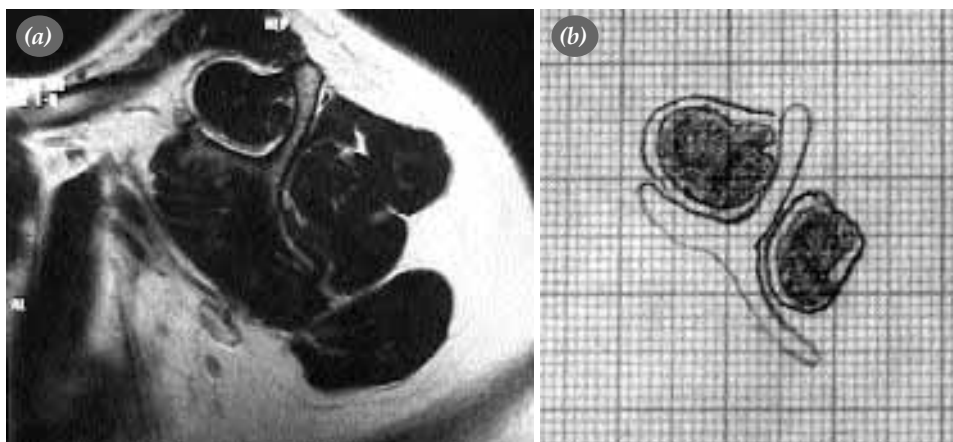
### Results

All patients had had a subacromial decompression procedure. The mean of the rotator cuff rupture was 2.5 cm (range 1 to 4 cm). There were three small, 16 mid and three large size ruptures. In seven patients the tears were L-shaped and retracted and these tears mobilized to lateral after side-to-side sutures. About one to three, 5.0 mm suture anchors have been used for rotator cuff repair. Two patients had had a biceps tenotomy as a result of a rupture more than 50% of its diameter.

The mean active forward flexion and external rotation increased from 105° to 160° ( $p < 0.05$ ) and from 41° to 44° ( $p > 0.05$ ), respectively (table 1).

Preoperatively, active adduction-internal rotation in 16 patients were noted at a level of L<sub>5</sub>; in four at L<sub>1</sub>; in one at PSIS and in one at T<sub>12</sub>. These levels improved to T<sub>7</sub> in two; T<sub>12</sub> in eleven; L<sub>1</sub> in nine. The strength of the supraspinatus and infraspinatus muscles significantly increased ( $p < 0.05$ ; table 1). The mean ASES and UCLA scores increased significantly ( $p < 0.05$ ; table 1).

The mean healing time was three months (range 1 to 12 months). Twenty patients (90.9%) were satisfied with the result of the treatment. Two patients (9.1%) were unsatisfied. A 59-years-old woman patient felt down the stairs two years ago and underwent an operation for a 2 cm rotator cuff tear. Her symptoms have recurred after handling a heavy object six months postoperatively. At her latest follow-up her main complaint was pain, she had difficulties in daily activities and uses analgesics fre-



**Figure 1.** (a, b) Calculation of the the rate of the fatty degeneration to the whole muscle mass on scapula Y planes on MRI by using standard millimetric papers.

**Table 1.** Functional and statistical results pre and postoperatively.

	Preoperatively	Postoperatively	p
<b>Range of Motion</b>			
Forward flexion	105° (40-150°)	160° (150-170°)	<0.05
Adduction-Ext rot.	41° (20-75°)	44° (20-75°)	>0.05
<b>Muscle strength</b>			
Infraspinatus	4.3 (3-5)	4.7 (4-5)	<0.05
Supraspinatus	3 (2-4)	4.5 (4-5)	<0.05
ASES scores	25.4 (10-45)	86.7 (63.3-100)	<0.05
UCLA score	10.6 (8-16)	25.6 (17-35)	<0.05
<b>Fatty degeneration</b>			
Supraspinatus	42.8% (4-60%)	43.8% (24-100%)	>0.05
Infraspinatus	18.6% (2-42%)	22.5% (7-63%)	>0.05

quently. Any restriction in joint motion was noted during examination. Strength of supraspinatus was one point less than the opposite side (4/5). On MRI, the supraspinatus tendon was constant. The other unsatisfied patient (68 year-old woman), felt down the stairs and her arm had hang on the banister. She had had a rotator cuff repair and biceps tenotomy operation for a 3 cm retracted rotator cuff tear and a more than 50% biceps tendon rupture. At her latest follow-up she had pain during overhead activities and used analgesics. Any restriction of motion in the joint have been noted. Muscle strength was the same as the preoperative strength (3/5). On MRI recurrent tear was detected.

On MRI scans, recurrent ruptures were detected in seven patients (31.8%). The recurrent tears were more smaller than before the repair, except one. In these seven patients, the mean ASES and UCLA scores significantly increased from 24.0 (range 11.6 to 38.8) to 89.7 (range 83.3 to 100) and from 10.4 (range 8 to 18) to 29.7 (range 20 to 32), respectively ( $p < 0.05$ ).

In all patients, in the sagittal plane, the preoperative rate of the fatty degenerated area of the supraspinatus muscle over whole tendon area increased from 42.8% (range 4 to 60%) to 43.8% (range 24 to 100%) postoperatively ( $p > 0.05$ ). The same rates for infraspinatus muscle were 18.6% (range 2 to 42%) and 22.5% (range 7 to 63%), respectively ( $p > 0.05$ ; figure 2a-f).

## Discussion

Snyder et al.<sup>(10)</sup> recommended arthroscopic repair for nonretracted, small, full thickness tears. However,

the indications for rotator cuff repair is being enlarged. It has been shown that, all size tears can be treated arthroscopically without adverse effects. There is no differences between the results of small, mid and large tears. Furthermore, it has been mentioned that arthroscopic repair can be performed in all ages.<sup>(11,12)</sup>

Demirhan and Esenyel<sup>(13)</sup> reported that arthroscopic rotator cuff tear repair is most suitable for all partial-thickness and small and mid full-thickness tears. Furthermore, they mentioned that, at older individuals, it may be possible to obtain successful results whenever debridement is performed simultaneously in large tears needing partial repair. They noted that this method may be used more frequently in the future.

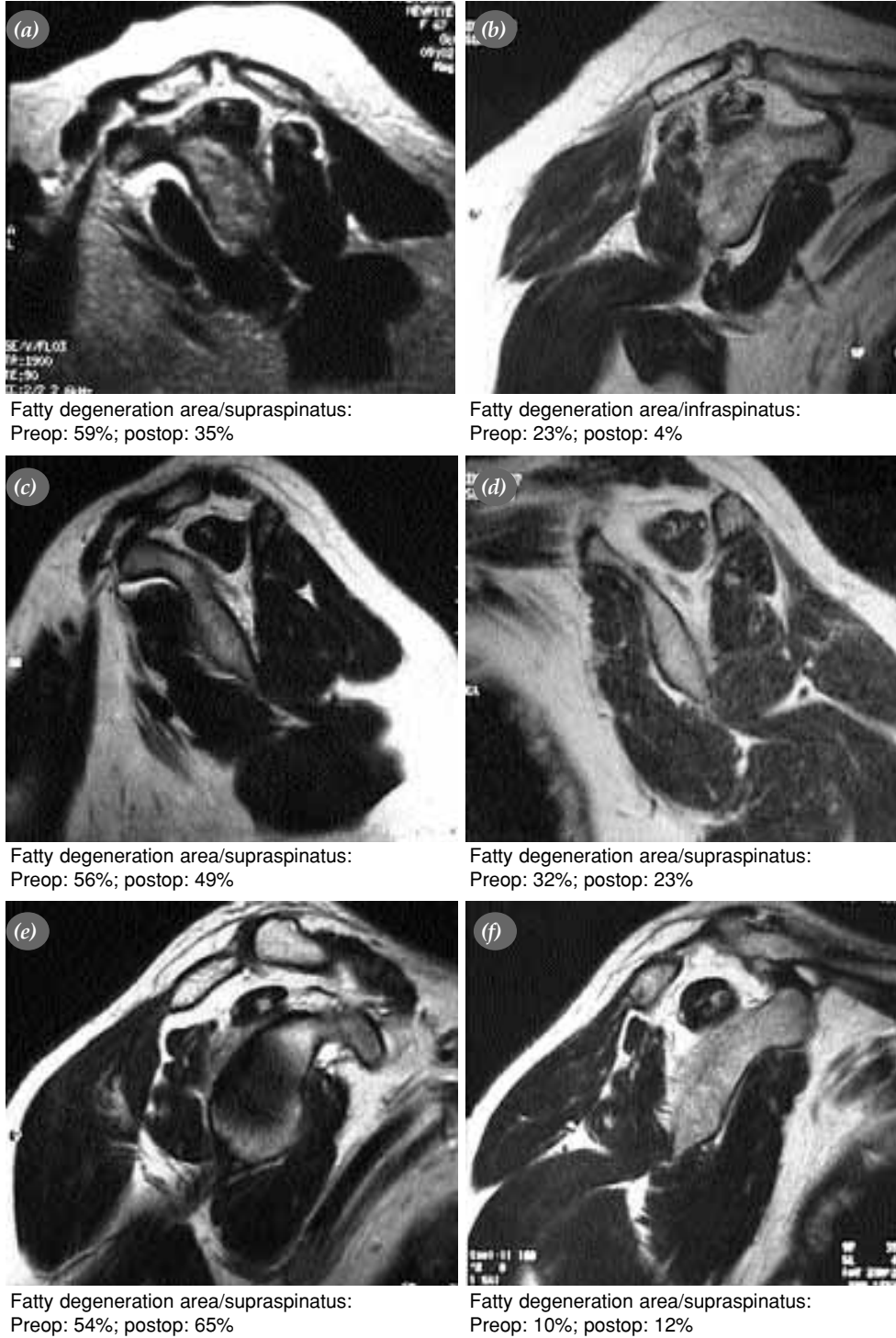
Burkhart,<sup>(14)</sup> repaired rotator cuff tears arthroscopically in 59 patients at whom he sutured simple tears directly to the bone; and in 13 patients with U-shaped tears he had sutured the tendon to the bone after a side-to-side repair. The UCLA scale increased from 14 to 29 postoperatively. In his study, he could not find statistically significant results between large and other sized tears and reported that the results were as successful as in the open repair.

The mean ASES and UCLA scores significantly increased from 25.4 to 86.7 and from 10.6 to 25.6, respectively ( $p < 0.05$ ). Twenty patients (90.9%) were satisfied and two were not, with the result of the treatment. The difference between the size of the tear and the repair results were not significant. It was observed that lateralization of the U-shaped and retracted tears by side-to-side sutures facilitates the procedure.

The most frequent complication after rotator cuff tear repairs is rerupture. After open repairs this complication rates are reported as high as 13-68%.<sup>(15)</sup>

Harryman et al.<sup>(16)</sup> have performed ultrasound to their 105 rotator cuff repair patients. The rerupture rate was found to be 20%. They reported that, in patients at whom single repair was performed, the lesion suspected during follow-up was more serious than that was

diagnosed peroperatively and the quality of the tissue effects the functional results. They found that, patients at whom the full thickness tears recurred, the strength of the shoulder joint decreased evidently than that with normal tendons.<sup>(16)</sup>



**Figure 2.** Pre and postop degeneration rates in; (a, b) 67 years old female patient, (c, d) 60 years old female patient and (e, f) 48 years old male patient.

Gazielly et al.<sup>(17)</sup> have performed ultrasound to their 100 patients who underwent rotator cuff repair and found rerupture in 24%, thinning in 11% and 65% seemed normal. The relation between type of the lesion and clinical results were not significant.

Knudsen et al.<sup>(16)</sup> observed the tendon constancy by MRI in 31 patients who underwent a single tendon repair and found 32% rerupture rate. However, relation between tendon constancy and functional results were not significant.

Jost et al.<sup>(15)</sup> observed 20 patients with recurrent tears after repair by MRI. The patients improved evidently at the postoperative period; the reruptures were smaller than that before the operation; although they had tears, their pain decreased and their functional status improved including abduction strength.

On MRI scans, recurrent ruptures were detected in seven patients (31.8%). In view of their physical examination and functional scores, the relation between recurrent tears and clinical results is not significant. Furthermore, on the MRI the clinical results don't differ between the normal and recurrence patients. The clinical improvement of our patients may be explained by the mechanism described by Loehr et al.<sup>(19)</sup> as long as the infraspinatus is not damaged the centralization function of the rotator cuff does not alter.

Tears in rotator cuff tendons may cause progressive and irreversible degenerative changes in rotator cuff muscles. Atrophy and fatty degeneration may effect some clinical parameters such as, the foresight, the result and the strength of the repair. For this reason, it has been mentioned that it is important to perform the rotator cuff repair previous than these changes. Recently, studies that quantify the rotator cuff muscles by means of MRI have been reported. Tingart et al.<sup>(20)</sup>, in a cadaveric study reported that rotator cuff muscle mass can be measured by MRI.

We evaluated the rate of the intramuscular fatty degeneration to the total rotator cuff mass for supraspinatus and infraspinatus muscles separately, on MRI pre and postoperatively. This rate increased from 42.8% (range 4 to 60%) to 43.8% (range 24 to 100%) postoperatively in the supraspinatus muscle ( $p>0.05$ ). The same rates for infraspinatus muscle were 18.6% (range 2 to 42%) and 22.5% (range 7 to 63%), respectively ( $p>0.05$ ). It is observed that the preoperative

fatty degeneration did not improve postoperatively.

We observed that the fatty degeneration in the rotator cuff muscles don't resolve after the operation and clinical results are not in relation with relatively high recurrent tear rates. We concluded that, these negative factors don't have a role on the successful results obtained after the arthroscopic repair of the full thickness rotator cuff tears.

## References

1. Neer CS 2nd. Anterior acromioplasty for the chronic impingement syndrome in the shoulder: a preliminary report. *J Bone Joint Surg [Am]* 1972;54:41-50.
2. Yamaguchi K, Levine WN, Marra G, Galatz LM, Klepps S, Flatow EL, et al. Transitioning to arthroscopic rotator cuff repair: the pros and cons. *Instr Course Lect* 2003;52:81-92.
3. Gartsman GM, Khan M, Hammerman SM. Arthroscopic repair of full-thickness tears of the rotator cuff. *J Bone Joint Surg [Am]* 1998;80:832-40.
4. King GJ, Richards RR, Zuckerman JD, Blasler R, Dillman C, Friedman RJ, et al. A standardized method for assessment of elbow function. Research Committee, American Shoulder and Elbow Surgeons. *J Shoulder Elbow Surg* 1999;8:351-4.
5. Ellman H, Hunker G, Bayer M. Repair of the rotator cuff. End-result study of factors influencing reconstruction. *J Bone Joint Surg [Am]* 1986;68:1136-44.
6. Owen RS, Iannotti JP, Kneeland JB, Dalinka MK, Deren JA, Oleaga L. Shoulder after surgery: MR imaging with surgical validation. *Radiology* 1993;186:443-7.
7. Zanetti M, Gerber C, Hodler J. Quantitative assessment of the muscles of the rotator cuff with magnetic resonance imaging. *Invest Radiol* 1998;33:163-70.
8. Goutallier D, Postel JM, Bernageau J, Lavau L, Voisin MC. Fatty muscle degeneration in cuff ruptures. Pre- and postoperative evaluation by CT scan. *Clin Orthop Relat Res* 1994;(304): 78-83.
9. Fuchs B, Weishaupt D, Zanetti M, Hodler J, Gerber C. Fatty degeneration of the muscles of the rotator cuff: assessment by computed tomography versus magnetic resonance imaging. *J Shoulder Elbow Surg* 1999;8:599-605.
10. Snyder SJ, Pachelli AF, Del Pizzo W, Friedman MJ, Ferkel RD, Pattee G. Partial thickness rotator cuff tears: results of arthroscopic treatment. *Arthroscopy* 1991;7:1-7.
11. Gartsman GM, Khan M, Hammerman SM. Arthroscopic repair of full-thickness tears of the rotator cuff. *J Bone Joint Surg [Am]* 1998;80:832-40.
12. Stollsteimer GT, Savoie FH 3rd. Arthroscopic rotator cuff repair: current indications, limitations, techniques, and results. *Instr Course Lect* 1998;47:59-65.
13. Demirhan M, Esenyel CZ. All arthroscopic treatment of rotator cuff tears. [Article in Turkish] *Acta Orthop Traumatol Turc* 2003;37 Suppl 1:93-104.
14. Burkhart SS. Arthroscopic treatment of massive rotator cuff tears. *Clin Orthop Relat Res* 2001;(390):107-18.
15. Jost B, Pfirrmann CW, Gerber C, Switzerland Z. Clinical outcome after structural failure of rotator cuff repairs. *J Bone Joint Surg [Am]* 2000;82:304-14.
16. Harryman DT 2nd, Mack LA, Wang KY, Jackins SE, Richardson ML, Matsen FA 3rd. Repairs of the rotator cuff. Correlation of functional results with integrity of the cuff. *J*

- Bone Joint Surg [Am] 1991;73:982-9.
17. Gazielly DF, Gleyze P, Montagnon C. Functional and anatomical results after rotator cuff repair. *Clin Orthop Relat Res* 1994;(304):43-53.
  18. Knudsen HB, Gelineck J, Sojbjerg JO, Olsen BS, Johannsen HV, Sneppen O. Functional and magnetic resonance imaging evaluation after single-tendon rotator cuff reconstruction. *J Shoulder Elbow Surg* 1999;8:242-6.
  19. Loehr JF, Helmig P, Sojbjerg JO, Jung A. Shoulder instability caused by rotator cuff lesions. An in vitro study. *Clin Orthop Relat Res* 1994;(304):84-90.
  20. Tingart MJ, Apreleva M, Lehtinen JT, Capell B, Palmer WE, Warner JJ. Magnetic resonance imaging in quantitative analysis of rotator cuff muscle volume. *Clin Orthop Relat Res* 2003;(415):104-10.